

The 4th ISMISS

The 14th MISS Summit Forum

March 25 fri. – April 24 sun.

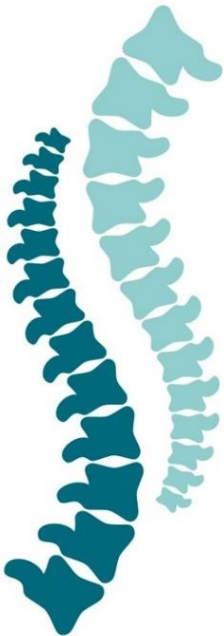Aichi Spine Hospital

honorary president
Hansjoerg Leu.
Gun Choi
Dezawa Akira

president
Koichi Sairyo

chairman
Fujio Ito
Zenya Ito

board member
Abdullah Merter, Alfonso García Chávez, Arvind Bhave, Arvind Kulkarni,
Ayhan Cömert, Byapak Paudel, Byeong cheol Rim, Christian
Morgenstern, Cigdem Mumcu, Daisuke Sakai, Elmer Jose Arevalo
Meceda, Hidetomi Terai, Hiroki Yoshimatsu, Hyeun Sung Kim, Javier
Quillo Olvera, Jin Hwa Eum, Jun Ho Lee, Jwo-Luen Pao, Kai-Uwe
Lewandrowski, Ken Ishii, Keng-Chang Liu, Kuniyoshi Tsuchiya, Malcolm
Pestonji, Masataka Sakane, Masatsune Yamagata, Michael Schubert,
Nobuyuki Shimokawa, Nurbyek Baban, Rafael Cruz Bundoc, Seiji
Yamaya, Shoichi Kokubun, Son Sang kyu, Tarik Yazar, Tatsushi Inoue,
Tolgay Satana, Verapan Kuansongtham, Wiwat Wajanavisit, Yi Hung
Huang, Yoshinori Kyoh, Chien-Min Chen, Shigeki Urayama, Kazunari
Fushimi



INDEX

Honorary president

S-1 Gun Choi

President's lecture

A-1 Koichi Sairyo

Chairman's lecture

B-1 Fujio Ito

B-2 Zenya Ito

Special lecture

C-1 Abdullah Merter

C-2 Alfonso García Chávez

C-3 Arvind Bhave

C-4 Arvind G Kulkarni

C-5 Ayhan Cömert

C-6 Byapak Paudel

C-7 Byeong cheol Rim

C-8 Christian Morgenstern

C-9 Cigdem Mumcu

C-10 Daisuke Sakai

C-11 Elmer Jose Arevalo Meceda

C-12 Hidetomi Terai

C-13 Hiroki Yoshimatsu

C-14 Hyeun Sung Kim

C-15 Javier Quillo olvera

C-16 Jin Hwa Eum

C-17 Jun Ho Lee

C-18 Jwo-Luen Pao

C-19 Kai-Uwe Lewandrowski

C-20 Ken Ishii

C-21 Keng-Chang Liu



- C-22 Kuniyoshi Tsuchiya
- C-23 Malcolm Pestonji
- C-24 Masataka Sakane
- C-25 Masatsune Yamagata
- C-26 Michael Schubert
- C-27 Nobuyuki Shimokawa
- C-28 Nurbyek Baban
- C-29 Rafael Cruz Bundoc
- C-30 Seiji Yamaya
- C-31 Shoichi Kokubun
- C-32 Son, Sang Kyu
- C-33 Tarik Yazar
- C-34 Tatsushi Inoue
- C-35 Tolgay Satana
- C-36 Verapan Kuansongtham
- C-37 Wiwat Wajanavisit
- C-38 Yi-Hung Huang
- C-39 Yoshinori Kyoh
- C-40 Chien-Min Chen
- C-41 Shigeki Urayama
- C-42 Kazunari Fushimi

Lectures

- D-1 Abdul Kadir Hadar
- D-2 Akarawit Asawasaksakul
- D-3 Ali Hammed
- D-4 Bhupesh Patel
- D-5 Chaiyaporn Siramanakul
- D-6 Chang, Chien-Chun
- D-7 Ching-Hsiao Yu
- D-8 Chul-Woo Lee
- D-9 Gun Keorochana
- D-10 Kwan-Su (David) Song
- D-11 Marcio Robertti Ramalho Da Cunha
- D-12 Matee Phakawech
- D-13 Meng-Huang Wu

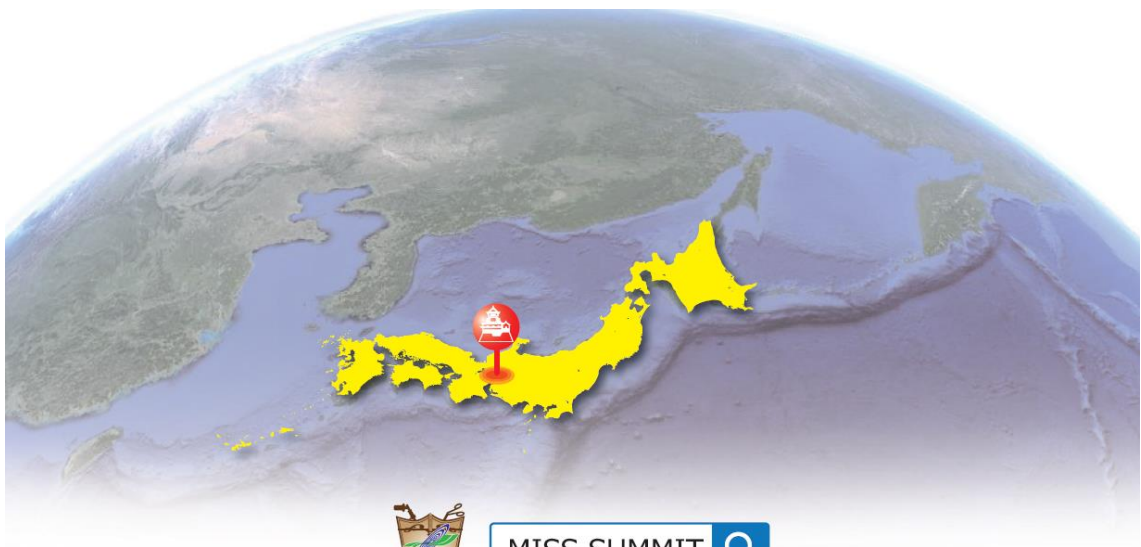

- D-14 Nantawat Uttamo
- D-15 Pradyumna Pai Raiturkar
- D-16 Saran Pairuchvej
- D-17 Seok-Bong Jun
- D-18 Songwut Sirivitmaitree
- D-19 Urawit Piyapromdee
- D-20 Zhang Wei
- D-21 Shisheng He
- D-22 En Song




Program

Honorary president



<http://missummit.com>



Title

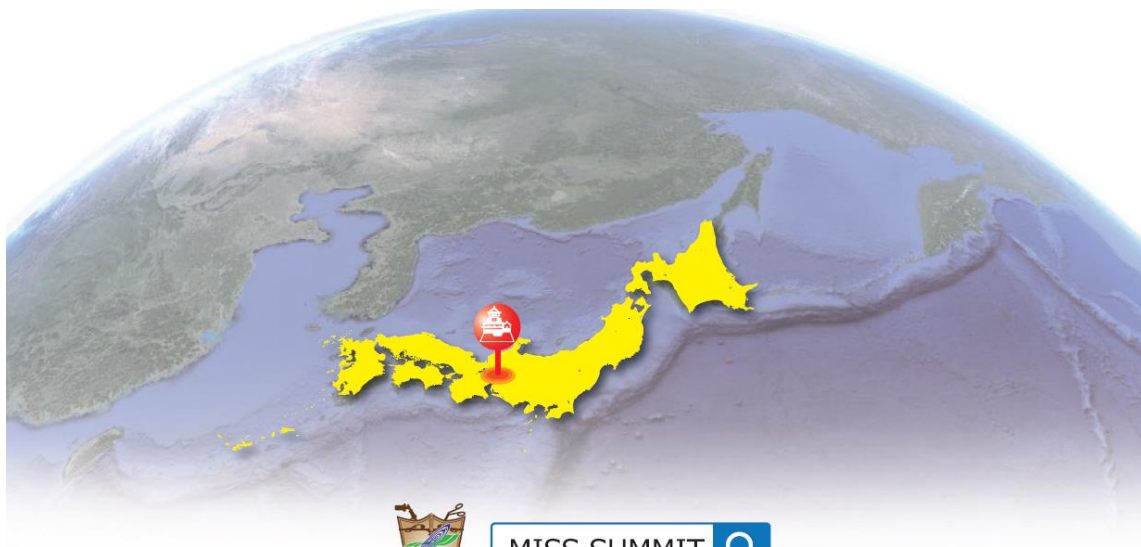Gun Choi
Pohang Wooridul Hospital

Education and Professional Work

cv


Program

President's lecture



MISS SUMMIT 

<http://missummit.com>



Full-Endoscopic Surgery for Professional Athletes: Discectomy, Foraminotomy, Thermal Annuloplasty and Disc Cleaning.

Koichi Sairyo

Department of Orthopedics, Tokushima University

In this educational lecture, I will explain the pathology of the low back pain in professional athletes, such as herniated disc, foraminal stenosis, discogenic pain and type 1 Modic change (MC). I prefer to do transforaminal (TF) approach, since I am the student of great Professor Tony Yeung.

Using TF approach, the full-endoscopic spine surgery can be done under the local anesthesia with just 8mm skin incision. That should be the minimally invasive spine surgery in the world. Currently.

Any type of the herniated disc can be removed with TF-FESS. Using the high speed drill, foraminal stenosis is also solved with FESS-foraminotomy. As the pain generator for the discogenic pain, high signal intensity zone (HIZ) at the posterior annulus fibrosus on T2-MRI has been proposed. Recently, Professor Yeung proposed the toxic annular tear (TAT) in discography and on CT-discography. To treat the pathology, radio-pulse thermal annuloplasty is useful. With the bipolar, cauterization of the HIZ and TAT can be done. Type 1 MC is another pathology causing low back pain in professional athletes. The surgical gold standard for type 1 MC is fusion; however, very recently, I established the FESS-disc cleaning surgery for this pathology. It is very useful to treat the endplate inflammation.

Most of the professional athletes are having the FESS surgery during season-off; then, they can return in the next season successfully. Even though, when they undergo FESS in season, they can return about 3 months after surgery.

In conclusion, there are several pathology of low back pain in professional athletes, and mostly they can be treated by FESS without losing additional season.

Education and Professional Work

Professor and Chairman, Department of Orthopedics, Tokushima University, Tokushima, Japan.

1988: MD degree, Tokushima University School of Medicine

1994: PhD degree, Tokushima University Graduate School of Medical Sciences

1995-1997: Post Dr. follow, University of Iowa, Iowa, USA

1998: Assistant Professor, Tokushima University Hospital

1999: Associate Professor, Tokushima University School of Medicine

2003-2005: Post Dr. follow, University of Toledo, Ohio, USA

2010: Associate Professor, Teikyo University Mizonokuchi Hospital

2013- present: Professor and Chairman, Tokushima University

International Society

International Society for Study of the Lumbar Spine: **ISSLS** (active member)

International Society for the advancement of the spine surgery: **ISASS** (member)

International Society of Endoscopic Spine Surgery: **ISESS** (Board member candidate)

International Intradiscal Therapy Society: **IITS** (Congress President 2021)

International Society for Minimal Intervention in Spinal Surgery: **ISMIS** (Asia representative)

Asian Congress Minimally Invasive Spine Surgery: **ACMISST** (Board member, Japan representative)

Pacific Asian Society for Minimally Invasive Spine Surgery: **PASMISS** (Board member)

World Congress Minimally Invasive Spine Surgery: **WCMSST** (Congress President 2021)

Japanese Society

Japanese Orthopaedic Association **JOA** (Board member)

Japanese Society for Spine Surgery and Related Research: **JSSR** (Board member, education committee)

Japanese Orthopaedic Society for Sports Medicine: **JOSSM**

(Society vice president since 2019, CONGRESS PRESIDENT 2018)

Japanese Society of the Minimally Invasive Spine Surgery: **JASMISS**

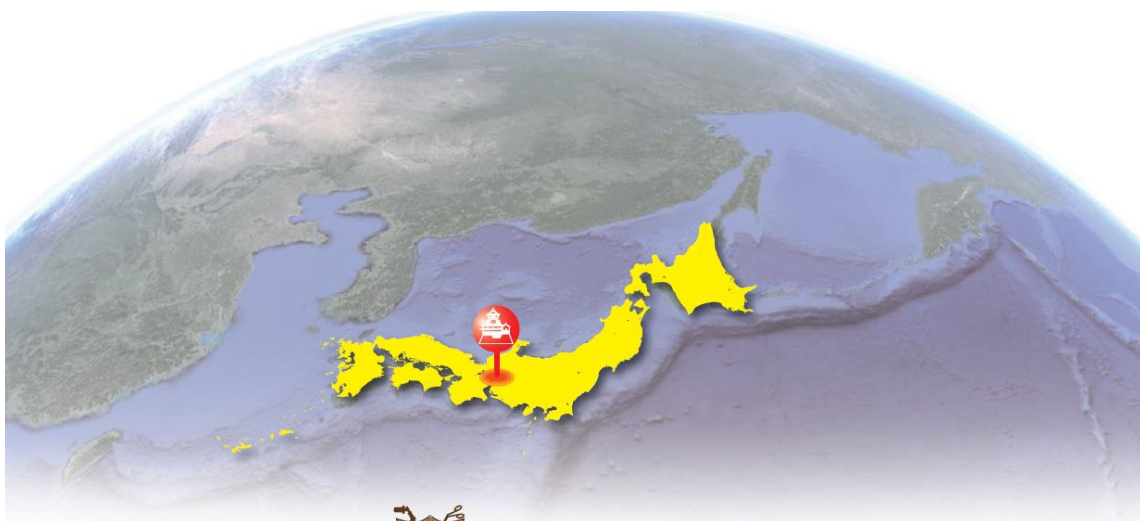(Society President since 2020, CONGRESS PRESIDENT 2019)

Japanese Society of the full-endoscopic trans-Kambin lumbar Interbody Fusion: **JEKLIF**

(Society President since 2020, CONGRESS PRESIDENT 2020&2022)

Program

Chairman's lecture



MISS SUMMIT 

<http://missummit.com>



Percutaneous Full-Endoscopic Lumbar Interbody Fusion (PELIF) of any lumbar level from L2/3 to L5/S1

Fujio Ito
President of Aichi Spine Hospital

Background: Various methods of lumbar interbody fusion surgery have been performed for lumbar interbody instability. PLIF and TLIF have risks such as dura damage and neuropathy due to invasive spinal canal, and damage to the back muscles and resection of articular joints were also relatively invasive. XLIF, OLIF and ALIF have sometimes a risk of serious damage to the intestines, ureters, great vessels, segmental arteries, upper and lower splanchnic nerves (retrograde ejaculation), peritoneum, and bladder.

Objective: To avoid those complications, we have developed a percutaneous full endoscopic trans-Kambin's safety triangle lumbar interbody fusion (PELIF) with an 8 mm outer sheath. Intervertebral disc and soft-cartilage endplate can be resected thorough Kambin's safety triangle. Lumbar intervertebral instability cases were fused using an intervertebral cage (sometimes expandable cage) and percutaneous pedicle screws (PPSs). We would like to examine its invasiveness, results, problems, etc.

Methods: Rotate the outer-sheath cutter with a sharp edge and remove the intervertebral disc and endplate from one side with wide foramen or radiculopathy. The bilateral decompression is performed at L5/S1 level. Severe instability segment is fused with two cages. After enlarging foramen, one or two expandable cages are sandwiched between the two L-shaped retract sliders with protecting the exiting roots by the round outer surface. The cancellous bone collected from the pelvis with 5 mm trephine is filled through the outer-cylinder.

Results: Cases were 29 (15 males and 14 females), 58.3 ± 14.2 years old. In each case, only one segment was targeted, and L2/3: 1 case, L3 / 4: 5 cases, L4 / 5: 16 cases, and L5 / S: 7 cases. The breakdown of the disease names was as follows : 15 cases of degenerative spondylolisthesis, 2-lumbar instability, 3-spondylolytic spondylolisthesis, 3-spondylolysis, 3-bilateral foraminal stenosis and 3-degenerative vacuumed disc change. One year later, the Macnab's evaluation showed that 26 of 29 cases were excellent or good. Interbody fusion was completed in 28 cases on CT. In one case, the irritating symptoms of the exiting root persisted for three to six months. The patient with spinal canal stenosis showed a magnified image on MRI. No cases of infection, dura mater / nerve damage, hematoma were observed.

Conclusions: PELIF is indirect decompression method by stretching redundant thickened ligament and expanding the spinal canal. The dura, intestine, and large blood vessels don't appear in the surgical field. If there is radiculopathy due to disc herniation or lateral recess stenosis, it is also possible to decompress them directly.

Education and Professional Work

Visiting professor of spine surgery, department of neurosurgery, Fujita Health University
Chairman of 1st ISMISS combined with 10th MISS Summit Forum in 2017
Chairman of 2nd ISESS (International Society of Endoscopic Spine Surgery)
and 2nd ISMISS (International Society of Minimal Intervention in Spine Surgery)
combined with 11th MISS Summit Forum in 2018
Chairman of 4th ISMISS combined with 14th MISS Summit Forum in 2021

Secretary-general of the Japan Spine Dock Society
President of MISS Summit Forum at Aichi Spine Hospital (Annual meeting)

MEMBERSHIPS

The Japanese Orthopaedic Association
Japanese Society for the Study of Endoscopic & Minimally Invasive Spine Surgery
Japanese Society of Lumbar Spine Disorders
Honorary board member of PASMISS
Board member of ACMISST
CEO of MISS Summit Forum



UBE vs another OP

Zenya Ito

Aichi Spine Hospital

Background:

Many minimum invasive surgery against lumbar canal stenosis was performed. UBEL is also very small invasive surgery. However the utility of UBEL against another MIS technique is not reported. The purpose of this study is to compare clinical results of another surgery with those of UBEL in patients with single-level lumbar spinal canal stenosis.

Methods

The subjects consisted of 262 patients that underwent MEL:139 cases, 81 PEL cases and UBEL:42 cases who were followed up for at least 6 months. All patients had lumbar canal stenosis for one level. Outcomes of the patients were assessed with the duration of surgery, the bone resection area in 3DCT, the facet preservation rates in CT axial imagery, visual analogue scale (VAS) for low back pain, the Oswestry Disability Index (ODI), and the EuroQol 5 Dimension (EQ-5D). Statistical analyses were carried out using a student-t test and an χ^2 test. A p-value of <0.05 were considered significant. For statistical analysis, we used the software program SPSS.

Results

The bone resection area in 3DCT was 1.5 for MEL vs 1.0 cm² for UBEL (p<0.05). The facet preservation rates on the advancing side and the opposite side were 78% vs 86% (advancing side: MEL vs UBEL) and 85% vs 94% (opposite side). (p<0.05)

The VAS(low back pain) score, VAS(leg pain), ODI and EQ-5D significantly dropped in both group at final period (p<0.05), however exhibiting no between the two groups at each period. MEL resulted in greater numbers of complications - being 5 cases of hematoma paralysis, 8 cases of dura injury, 2 cases of reoperation, as opposed to zero cases of hematoma paralysis and only 2 cases of dura injury resulting from UBEL. And then UBEL was shorter operation time than PEL. (p<0.05)

Conclusions

The UBEL method is a more useful technique than the MEL method as it requires a smaller bone resection area and produces fewer complications and good result as PEL.

Education and Professional Work

EDUCATION:

April 1992 to March 1998, student of Nagoya University School of Medicine, obtained the M.D. degree
 April 2004 to March 2008, Ph.D. student in the Postgraduate Course of Nagoya University School of Medicine
 Nagoya University

LICENSURE & CERTIFICATION:

- National Board of Medicine, Registration No. 392818
- Board-certified Spine Surgeon approved by the Board of the Japanese Society for Spine Surgery and Related research

FELLOWSHIP OR STUDY ABROAD:

- 2008/June APOA spine travelling fellowship selected as the only member from Japan
- 2009/Aug-2010/Sep Emory spine center clinical and research fellowship

ACADEMIC APPOINTMENTS:

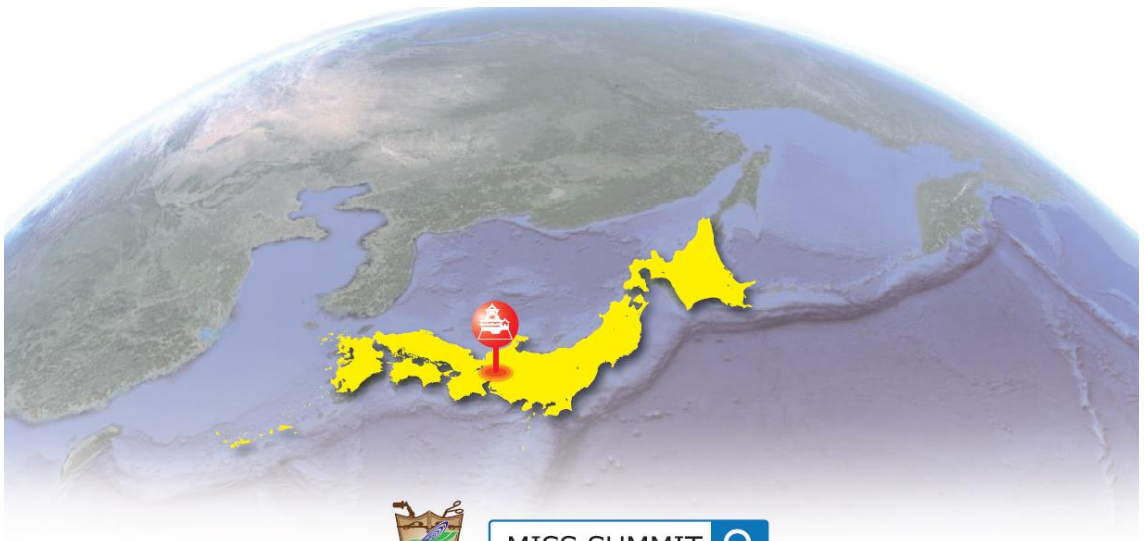Assistant Professor of orthopedic section in Nagoya University

HOSPITAL APPOINTMENTS:

1998/Apr-2003/Mar Nagoya 1st red cross Hospital
 2003/Apr -2004/Sep National center for Geriatrics and Gerontology
 2004/Sep -2005/Mar Atsumi Hospital
 2005/Apr -2008/Mar Student in the Postgraduate Course of Nagoya University School of Medicine
 2008/Apr -2009/Jul Medical staff in Nagoya University Hospital
 2009/Aug-2010/Sep International clinical fellowship of Emory Spine Center
 2010/Oct-2011/Mar Toyohashi municipal Hospital
 2011/Apr-2016/Mar Assistant professor in Nagoya University Hospital
 2016/Apr-2017/Mar Aichi Spine Institute vice president
 2017/Apr -Present Aichi Spine Hospital Chair

Program

Special lecture



MISS SUMMIT 

<http://missummit.com>



Unilateral biportal endoscopic dural repair with bovine pericardium collogen patch

Abdullah Merter*, Mustafa Onur KARACA**

*Associate Professor, Ankara University School of Medicine

**Orthopaedic Surgeon, Ankara University School of Medicine

Background

Unilateral biportal endoscopic surgery (UBES) is one of the popular minimally invasive spine surgery techniques used to treat lumbar degenerative spinal diseases. More effective and safer surgery can be performed compared to uniportal techniques, thanks to its ability to be performed without compromising visual capacity and hand movements. However, dural injury is the most common complication of endoscopic spine surgery with an incidence rate of 1.7% to 4.3%. Conversion to open surgery for direct repair could become necessary during endoscopic spinal surgery. To date, there is a lack of consensus in the literature regarding the management of incidental durotomy in endoscopic spine surgery. . Vycril mesh, fibrin sealant patch and direct endoscopic repair (with suture or clips) have recently been described in the literature for the endoscopic treatment of incidental dural tears. In this study, we used bovine pericardium collogen patch (Tutopatch) to treat incidental dural tears endoscopically and we aimed to share the clinical and radiological results of the cases.

Objectives:

We aimed to present the clinical and radiological results of incidental dural ruptures treated endoscopically with Tutopatch.

Methods:

We retrospectively reviewed the medical and radiographic records of surgically treated patients who underwent UBES at a single institute between January 2018 and December 2019. In the present series, during the original surgery to treat the dural rupture, repair was performed according to the so-called extradural technique: a thin layer of fibrin glue (Tisseel; Baxter AG, Vienna, Austria) was injected to seal the arachnoid, then a dural substitute, bovine dehydrated pericardium (Tutopatch; Tutogen Medical GmbH, Neunkirchen am Brand, Germany) was positioned in the extradural space covering the dural opening, dragging the dural substitute in overlay position.

Clinical outcomes were evaluated using modified Macnab criteria, Oswestry disability index (ODI), and visual analogue scale (VAS) of the leg and back. Cerebrospinal fluid (CSF) leakage or related problems, incidence rate and radiological results at postoperative 1st month MRI were investigated.

Results:

1003 patients, representing 1562 levels, underwent UBES. Fifteen dural injuries occurred, and the incidence rate was 1.4%. 14 of patients with dural rupture was on the central cauda equine and one of them occurred on the traversing root. No cases progressed to surgical site infection, infectious spondylitis, cerebrospinal fluid leakage, pseudomeningocele, meningitis or head pain. Overall for mean and standard deviation preoperative, 1 week postoperative, 3 months, and final follow-up for visual analog scale were 7.8 ± 1.4 , 3.6 ± 1.2 , 2.5 ± 1.1 , and 2.0 ± 1.2 , and for Oswestry Disability Index are 72.5 ± 8.0 , 34.3 ± 8.8 , 26.6 ± 6.9 , and 23.4 ± 7.0 . 13 of the patients recovered "good" and 2 with "excellent" results according to the Macnab criteria.

Conclusion:

Dural injury during UBES can occur because of the various anatomical features of the meningo-vertebral ligaments, adhesion or dural folding. A dural rupture can be safely controlled with a simple patchy reinforcement (Tutopatch) under unilateral biportal endoscopic vision.

Education and Professional Work

ABDULLAH MERTER M.D.

Current Address

Associate Professor

Ankara Medicine Faculty, Ibn-i Sina Hospital

Orthopaedics and Traumatology Department

/Ankara/Turkey

e-mail: dr.merter@gmail.com

Date of Birth 06.06.1985

EDUCATION

2018-2019 Spine fellowship researcher (Minimally Invasive Endoscopic Spine Surgery), Aichi Spine Hospital, Inuyama-shi, Aichi prefecture, JAPAN

2018 Clinical fellowship, Minimally Invasive Endoscopic Spine Surgery, ParkWeonWook Spine Hospital, Busan, SOUTH KOREA

2009-2015 Research assistant, Orthopaedics and Traumatology Department, Ankara University Medicine Faculty, Ankara, TURKEY



Transforaminal Endoscopic Foraminotomy Instead of Fusion Surgery in Foraminal Stenosis Cases

Alfonso García Chávez
Hospital Angeles Tijuana

In recent years there has been a special interest towards Endoscopic Spine Procedures. I will share some concepts on “Transforaminal Endoscopic Foraminoplasty as an option to fusion surgery in foraminal stenosis cases”.

Endoscopic foraminotomy was possible thanks to a number of events. The major milestone was the description of the “transforaminal safe working corridor” known as the Kambin’s Triangle. This step made it possible for other surgeons to continue exploring the foraminal region by further developing highly specialized instruments to better adapt the visual aid of the endoscope and provide extra room for the exiting nerve root, giving start to a new era in the endoscopic surgery approaches, by broadening its indications to include other pathologies that couldn’t be safely performed before.

The setup for Transforaminal Endoscopy is credited to Dr. Anthony Yeung. And later by Dr. Thomas Hoogland. Yeung developed a working channel scope with integrated irrigation system and Hoogland introduced a canulated blunt tip hand-controlled drill bit to perform percutaneous foraminotomy. Next came strong competitors that continued to improve the design of their basic instrument set, both for differentiation and increase safety when decompressing the aging spine. We are now experiencing the Golden Age, where the rapid interest and usability of these systems has produced high quality evidence to support the integration of this toolset to the already immense offerings of spine surgical innovations.

As we move forward and experience this Golden Age, we can now communicate that: -Endoscopic Surgery has broader indications than 10 yrs ago. -That it offers an improved surgical view -It is a muscle preserving technique -With less bleeding, less postop pain, reduced infection rate and a fast recovery.

Education and Professional Work

Dr. Alfonso García Chávez Minimally Invasive and Endoscopic Spine Surgery
+52 (664) 635 1852
+52 1 (664) 204 3196
[facebook.com/espaldasaludable](https://www.facebook.com/espaldasaludable)
[linkedin.com/espaldasaludable](https://www.linkedin.com/company/espaldasaludable)
@saludablesalda@espaldasaludable.mx

Certified by “International UBE Spine Surgery Society”
2017 Active Member “North American Spine Society” 2017 NASS Member ID 420499
2017 JOIMAX® Faculty
2019 AOSpine plus member ID 100024980
2020 Elsevier Editorial Reviewer.
2021 AMCICO (Mexican Spine Surgeons Association) Member
2021 Faculty, ESPINEA Universidad de Karlsruhe, Royal College of Surgeons of Edinburgh (Título en trámite)



Transforaminal Endoscopic surgery in challenging conditions

Arvind Bhave
Deenanath Mangeshkar Hospital

Transforaminal endoscopic discectomy is frequently performed minimally invasive surgery now a days. Main indication being prolapsed lumbar intervertebral disc, causing unilateral leg pains which is not relieved by conservative treatment.

In this presentation, endoscopic discectomy in challenging multiple situations is presented.

Endoscopic discectomy can be successfully used in superior or inferiorly migrated disc prolapse. Extraforaminal herniations, reduce surgery in failed back syndrome.

Result: Percutaneous Endoscopic discectomy can be successfully done in multiple disc herniation pathologies with satisfying results.

Education and Professional Work

NAME: DR. ARVIND BHAVE.

ADDRESS: C/O: BHAVE HOSPITAL, 48, PARVATI INDUSTRIAL ESTATE, PUNE-SATARA RD. PUNE, MAHARASHTRA INDIA. 411009. PHONE/FAX NO +91-20-24225323.

E-MAIL: arvindbhave05@gmail.com,

RESIDENCE: D-202, Pate Sanskruti, 1231 Sahakarnagar, PUNE Maharashtra, INDIA, 411009. PHONE NO: +91-20-24200200.

BIRTH DATE: 05-05-1964. (FIFTH MAY NINETEENSIXTYFOUR.)

AWARDS RECEIVED:

*ONE OF THE TEN OUTSTANDING YOUNG PERSONALITIES OF PUNE. [TOYP].

*INTERNATIONAL FELLOWSHIP-GOVT. OF ISRAEL-FOR INTERNATIONAL POSTGRADUATE TRAINING COURSE IN ORTHOPAEDIC [SPINE] SURGERY at TEL-AVIV UNIVERSITY ISRAEL. 1998.

*BOMBAY ORTHOPAEDIC WOCHARDT FELLOWSHIP FOR 1998-99- [BOS SPINE FELLOW].

*BEST PAPER AWARD -at the Research Society Annual Conference of the B.J. MEDICAL COLLEGE, PUNE 1999.

*SELECTED FOR WORLD ORTHOPAEDIC CONCERN FELLOWSHIP FOR 2000.

*SELECTED FROM ASIAN SPINE SURGEONS FOR JAPANESE SPINAL FELLOWSHIP -2001.

*BEST PAPER AWARD at RESEARCH SOCIETY -BHARATI VIDYAPEETH DEEMED UNIVERSITY. -2000 & 2002 [TWO TIMES].



Is it not imperative to have a precise estimate of the burden of spinal osteoporosis for an individual and the community at large? Recommendations to designate quantitative-CT (Q-CT) to be the gold standard for detecting spinal osteoporosis

Arvind G Kulkarni
Mumbai Spine Scoliosis & Disc Replacement Centre

BACKGROUND: Globally, osteoporosis is the commonest denominator for most spinal disorders. Vertebral-compression-fractures (VCFs), implant-loosening, pseudarthrosis, proximal-junctional-failures, sagittal imbalance and revision surgeries challenged by osteoporosis are omnipresent. Preponderant component (80%) of spinal load is borne by the anterior column which happens to be the site of VCFs, pedicle-screw-purchase and interbody-fusions and is anatomically laden with trabecular bone. Trabecular bone strength is best evaluated using quantitative-CT(Q-CT). However, DXA (Dual X-ray absorptiometry) scan continues to be the investigation of choice to assess spinal bone density, despite realizing its well-known drawbacks. In view of the global liability of osteoporosis in terms of morbidity, mortality, financial and social implications, is it not imperative to have a precise estimate of the burden of spinal osteoporosis for an individual and the community at large?

OBJECTIVE: Refinement of guidelines for screening osteoporosis

METHODS: Bone mineral density (BMD) of post-menopausal women was evaluated using either Q-CT or DXA between January 2018-December 2020. Comparison studies of the distribution of age and T-scores of bone densities obtained from the two study groups: age-matched, sex-matched and common skeletal site of interest (L1-L4 vertebrae) were performed. Mann-Whitney test, correlation and regression analyses were performed, and bell curves were plotted.

RESULTS:

Out of 718 post-menopausal women that were evaluated, 447 underwent Q-CT (age 50-89) and 271 underwent DXA (age 49-89). The two groups were comparable with respect to age (p value > 0.5). The mean and mode T-scores obtained with Q-CT and DXA were found to be - 2.71, -3.8 and -1.63, -1.7 respectively. A significant difference in T-scores was observed in Q-CT and DXA groups (p-value <0.0001). Among patients who were screened using Q-CT, 58.16% were osteoporotic, 37.58% were osteopenic and 4.25% exhibited normal BMD, while the respective percentages in the DXA group were 30.63%, 49.82% and 19.55%.

CONCLUSION: Apparent spinal osteoporosis is just the tip of the iceberg. Vertebral trabecular bone takes the spotlight in the context of spinal osteoporosis and hence its precise evaluation is extremely critical for appropriate management. DXA underestimates spinal-BMD and is hence questionable. Q-CT on the other hand provides a more precise estimation of trabecular bone mineral density. The authors strongly recommend Q-CT to replace DXA as the gold standard for evaluation of spinal osteoporosis. This step will have a large global impact in minimizing the morbidity and mortality related to osteoporosis related spinal manifestations and surgical complications, thus ensuring safety and quality.

Education and Professional Work

Dr Arvind G Kulkarni is one of the pioneers of Minimally Invasive Spinal surgery and Artificial Disc replacement in India.

He is the Associate Editor of Journal of Minimally Invasive Spine Surgery and Techniques (JMISST, Korea). He is on the Editorial board of Asian Spine Journal (ASJ, Korea), International Journal of Spine Surgery (IJSS, USA), Indian Spine Journal (ISJ) and Journal of Clinical Orthopaedics (Official publication of Bombay Orthopaedic Society).

He is one of the few selected members on the review board of the prestigious international journal 'Spine'.

He is in the executive council of ASSI (Association of Spine Surgeons of India) in the educational and research task force and Secretary of MISSAB (Minimally Invasive Spine Surgeons of Bharat). He is one of the founder members of MISSAB. He served as Fellowship Officer for AO Spine-Indian Sub-continent. His team was recently awarded one of the Best Papers of 2021 in the International Safety in Spine Surgery for their project on 'Spine surgery Check-list' under Best New Methodologies and Techniques to Enhance Safety in Spine Surgery.



From anatomy of the spine to clinical applications: recent advances and translational research

Ayhan Cömert

Department of Anatomy, Ankara University

Chronic low back and neck pain is associated with intervertebral disc degeneration. Differentiation of notochord-like cells into chondrocyte-like cells is correlated with disc degeneration and aging. Disc's capacity for regenerating itself is exhausted over time. New idea is to direct and refine differentiation of adult and human-induced pluripotent stem cells into notochord-like and nucleus pulposus-like cells for use in novel cell-based therapies. Human-induced pluripotent stem cells (hiPSCs) have attracted much attention for their potential use in cell-based therapies. Additionally, treatment of degenerative disc disease with allogeneic mesenchymal stem cells, their long-term follow-up results were discussed. New studies are under discussion to valid alternatives for treatment of degenerative disc disease because was published that they can provide effective and durable pain relief together with objective improvements to disc degeneration. There are major limitations as difficulties to generalize the results to large populations, as well as the lack of detailed determination of the optimal dosage of cells. Anatomical protection neurovascular structures is important during transforaminal approaches. Here major vessels include the abdominal aorta, the inferior vena cava, and the common iliac arteries and veins, situated directly anterior to the lumbar spine. Injury to the great vessels and sympathetic and superior hypogastric plexus anterior to the intervertebral disc should be always kept in mind during disc surgery and instruments should not be inserted much into the disc space. However, serious complications may occur due to the proximity of the intervertebral disc to adjacent neurovascular structures. Anatomical investigations support that for instance cooled blood may enter the internal vertebral venous plexus from subcutaneous veins and that could very well serve both warming and cooling of the spinal cord. Additionally, injury to nerve roots and perforation into the anterior annulus fibrosis and anterior longitudinal ligament with major vascular injury is rare during surgical approaches. However, anatomical protection of epidural venous system during transforaminal approaches is an important advantage. The internal vertebral venous plexus was connected to segmental veins outside the vertebral column via intervertebral veins that run through the intervertebral foramen. It is known that, the veins from the erector spinae drained into intervertebral veins. Additionally, there are many clinical cases describing the symptomatic epidural venous engorgements and anatomic variations in the literature.

Education and Professional Work

PERSONAL DETAILS:

Address: Department of Anatomy Ankara University, School of Medicine
06100 Sıhhiye, Ankara, TURKEY

Profession: Professor of Anatomy

Nationalit: Turkish

Mail: comertayhan@yahoo.com ; comert@medicine.ankara.edu.tr

Cellular Phone: +90 535 8467218

Awards

- ISMISS Turkey 2011 Innovative research award, ISMISS Turkey Congress, Antalya, Turkey (“Morphometry and Anatomy of the Lumbosacral Dorsal Root Entry Zones”)
- Ankara University, School of Medicine, “Prof. Dr. Hikmet Yavuz” Best research award, 2008
- The American Society of Colon and Rectal Surgeons: The ASCRS Barton Hoexter, MD, Best Video Award: “Perineal anatomy for colorectal surgeons”, 2016

PROJECTS

The Scientific and Technological Research Council of Turkey TÜBİTAK 104S402 SBAG SBAG-AYD-479
Yumuşak ve sert doku malzeme deney sistemine elektronik veri toplama biriminin eklenmesi 2005 /2006

Turkish Neurosurgical Society Türk Nöroşirürji Derneği Araştırma Projesi. Deneysel akut omurilik yaralanmasında (spine injury) granülosit koloni stimulan faktörün (GCSF) antiinflatuar etkisi 2007

Celal Bayar University Research Projects, Celal Bayar Üniversitesi Bilimsel Araştırma Projesi Tıp 2005- 47 Sıçan beyinde fokal iskeminin matriks metaloproteinaz ve ekstraselüler matriks proteinlerinin dağılımlarına etkisinin immunohistokimyasal yöntemle değerlendirilmesi 2005/2007

The Scientific and Technological Research Council of Turkey TÜBİTAK 108S075 İnsan dişsiz çene kemiklerinin mikromekaniksel özelliklerinin incelenmesi 2008/2011



Disc, Pain generators, Percutaneous Full Endoscopic Management

Byapak Paudel

Grande Int. Hospital, Kathmandu, Nepal

Introduction:

Disc is an important structure of spine and when pathological it can be associated with low back pain with or without radiating or referred pain.

Disc degeneration/injury leads to Discogenic back pain, pain due to prolapsed intervertebral disc (PIVD) and stenosis related pain.

Treatment: Discogenic back pain: Now it can be managed by percutaneous full endoscopic technique. A landmark paper on percutaneous full endoscopic technique for management of discogenic back pain has been published. The most recent promising percutaneous full endoscopic technique uses laser for ablation of sinuvertebral nerve extradiscally with 96.1% good to excellent result. Prior treatment methods for discogenic back pain has less favorable outcome and has problems.

PIVD related pain: Now it can also be managed by percutaneous full endoscopic technique either by Interlaminar (PEILD) or Transforaminal (PETLD) approach. PETLD can be done through 3 routes. Results are equivalent to microsurgical discectomy with added benefits of Minimally Invasive spine Surgery. It can be done for all kinds of disc herniations with more than 96% success (98.1% as per endoscopic success grading/scoring). It can also be done successfully for high grade inferiorly migrated disc herniations by Suprapedicular Circumferential Opening Technique (SCOT technique).

Stenosis related pain: Now it can also be managed by percutaneous full endoscopic technique. The first landmark paper uses contralateral unilateral approach for decompression of bilateral spinal stenosis with 96 % good to excellent outcome. PESLD (Percutaneous Endoscopic Stenotic Lumbar Decompression) neither violates facet joint nor violates soft tissue. In previous microsurgical techniques there is problem of facet violation and soft tissue violation.

Endoscopic fusion: Literatures are coming up with equivalent or better outcome after endoscopic fusion to treat spinal pain.

Conclusion:

- Disc degeneration/injury leads to Discogenic back pain, pain due to prolapsed intervertebral disc (PIVD) and stenosis related pain.
- Percutaneous full endoscopic techniques are least invasive of minimally invasive spine surgery (MISS) having advantages of minimally invasive surgery (MIS) than open or microsurgical techniques.
- Discogenic back pain, PIVD and stenosis can be managed successfully by percutaneous full endoscopic techniques.
- Treatment of discogenic back pain, discectomy and stenosis decompression, fusion will all be percutaneous full endoscopic in near future.
- In due course of time all spinal problem can be solved by percutaneous endoscopic techniques.

Education and Professional Work

Dr. Byapak Paudel

DOB: 4th July 1973 AD (Nepal)

Qualification, Post

MD, MS (Ortho), Fellowship Minimally Invasive Endoscopic Spine Surgery

Consultant Orthopedic and Spine Surgeon

Assistant Director Spine Services, Grande International Hospital

Consultant Nepal Health Research Council (NHRC) for Spinal Trauma Registry- Nepal project

Faculty of National Board of Medical Specialties - Orthopaedics: Medical Education Commission Nepal

General Secretary Association of Spine Surgeons of Nepal (ASSN) –Present

Founder Joint Secretary Association of Spine Surgeons of Nepal (ASSN) Estd. 2012

Member Institutional Review Committee (IRC) Grande Int. Hospital- Approved by Nepal Health Research Council (NHRC)



A Incidental conversion of full endoscopic posterior cervical foraminotomy to unilateral biportal endoscopic posterior cervical decompressive laminectomy under lateral decubitus position with local anesthesia and sedation

Byeong cheol Rim

Department of Neurosurgery, RIMS neuroclinic, Cheongju-si,

This 46 years old man, his symptom was severe radiation arm pain, intractable arm pain was even not responded to epidural steroid injection neurolysis. It was planned to get the operation by full endoscopic posterior cervical foraminotomy for decompression at the level of C5/6, Right side.

Just after a puncture of skin and placing the working sleeve into the lesion site, incidental and mechanical failure of endoscope and instruments for a full endoscopic posterior cervical foraminotomy (PCF) under lateral decubitus position with local anesthesia.

At that time, we can not to do continue the planned operation, and so we convert it to biportal endoscopic posterior cervical foraminotomy under lateral decubitus position with local anesthesia.

This talk is something for this incidental conversion of endoscopic assisted posterior cervical foraminotomy or laminectomy under lateral decubitus position with local anesthesia. At first, we made a table tilted a little about 20~30 degrees from full lateral decubitus position of patient. We need a more skin puncture and making trajectory for endoscope by using serial dilation and a little 10mm more extended skin incision for placing transparent UBE plastic work sleeve for easy work of instruments in concern of cord damage because of heavy posterior cervical muscles and unfamiliar position of UBE in cervical operation. During the operation, also, epidural catheter used for injection of local anesthetics epidurally. we did not perform the discectomy, only decompressive laminectomy done. The result was very good, his pain was gone since 10 months ago. It was feasible that unilateral biportal endoscopic posterior cervical laminectomy with local anesthesia and can be a good alternative option for in case of unable full endoscopic posterior cervical foraminotomy. The other side we have to study more about the limitation and future applicable indication for endoscopic posterior cervical foraminotomy.

Education and Professional Work

Address

Office : Department of Neurosurgery

RIMS Neuroclinic

1360 Garosu-ro, HeungDeok-gu, Cheongju-si, Chungcheongbuk-do

South Korea

Post code) 28597

Tel: 043) 232- 6788

(82) 10 -6438-3379

E-mail : bcrim7533@gmail.com

Licensure and Certification

Licensed to Practice Medicine in Korea, 1994

Korean Board of Neurosurgery, 1999

Master of medicine (ChungBuk National University, College of Medicine), 1997

PhD. ChungBuk National University, College of Medicine, 2007



Advances in cervical endoscopic spine surgery - anterior and posterior approach and cervical fusion with the PSLD scope

Christian Morgenstern*, Rudolf Morgenstern

*Morgenstern Institute of Spine, Centro Médico Teknon,

Endoscopic cervical spine surgery has gained adoption in recent time due to the increasing popularity of endoscopic posterior cervical foraminotomy for foraminal herniations in the cervical spine. At the same time, endoscopic anterior cervical discectomy (ACD) has not seen a comparable widespread adoption. Reasons for this may relate to the anterior endoscopic approach being considered difficult and hazardous, as well as the popularity of the gold-standard open anterior cervical approach. Moreover, popularity of endoscopic cervical surgery has also been limited by the costs of investing in a separate cervical endoscope endoscope and instrumentation.

We want to introduce a case series and present clinical examples showing the applications of endoscopic ACD and endoscopic posterior foraminotomy using only one endoscope (Maxmore PSLD scope) that was originally designed for the lumbar spine. The advantages of using a lumbar endoscope for cervical spine surgery include increased versatility and robustness of the instruments, lower costs and excellent visualization. At the same time, we have developed custom instrumentations to facilitate the anterior approach with the PSLD scope.

We also present a case series of endoscopic ACD and fusion (ACDF) which allows us to place a cervical interbody cage through a 25mm skin incision. We believe that endoscopic ACDF has the advantages of excellent visualization and disk preparation with the endoscope, as well as less soft tissue disruption as the approach does not require dissection nor continuous soft tissue traction with a spreader

Education and Professional Work

Teaching instructor (international faculty) in international workshops for endoscopic spine surgery (AO Spine, Maxmore Spine, etc.)

Board certified orthopedic surgeon (German Board, Berlin)

Residency training at Charité Universitätsmedizin Berlin, Germany

Fellowship trained MIS and endoscopic spine surgeon

Publications / Societies

More than 100 abstracts and papers in international peer-reviewed journals and international conferences (NASS, Eurospine, AO Spine GSC, ISMISS, etc.)

Reviewer for more than 10 international journals

Member of NASS, Eurospine, AO Spine, ISASS, IEEE



Some Useful Tips for Biportal Endoscopy

Cigdem Mumcu

Republic of Turkey Ministry of Health Sultanbeyli State

Abstract:

UBE is a new endoscopic technique for treatment of all degenerative spine diseases. In this method two portals are used, and these two portals move in all directions independently. That is a big progress, its property offers a wide range of spectrum for indication. Moreover, the endoscopic trajectory has same steps as conventional microsurgery with excellent panoramic view. UBE has many advantages such as protection of the musculoligamentous complex, a smaller incision, less postoperative back pain and short hospitalization. Another advantage is that UBE does less postoperative morbidity by reducing incidence of epidural fibrosis. Furthermore all kinds of degenerative spine diseases such as herniated disc, spinal stenosis, revision surgery, fusion surgery, far out syndrome, facet cyst, many complicated cases and also spine deformities can be treated with UBE.

Such benefits of UBE surgery including simple discrimination of anatomic structures, tender manipulation of pathology with magnified endoscopic view, and detailed operative information might contribute to get successful result in all the spine pathologies.

Education and Professional Work

Dr. Mumcu has special training in Unilateral Biportal Endoscopy (UBE) by Dr. Sang Kyu Son, Busan Park Weon Wook Hospital in Korea. UBE is the last endoscopic spine procedure that highly effective on all degenerative spine diseases. Along with many other minimal invasive spinal procedures, Dr Mumcu is trained in Sacral Epiduroscopic Laser Disc Decompression (SELD) by Dr Kang Taek Lim at Seoul Good Doctor TeunTeun Hospital in Korea, Endoscopic Spine Surgery by Dr Gun Choi at Pohang Wooridul Hospital in Korea, and Regenerative Medicine (platelet-rich-plasma and stem cell) and Endoscopic Spine Procedures by Dr Atif Malik at American Spine Center in USA.

She is a member of Turkish Society of Unilateral Biportal Endoscopy, Turkish Neurosurgery Society, Turkish Spinal and Peripheral Nerve Surgery Society, Turkish Spine Society (TOD), AOSpine, International High-Tech Spine Society (IHTSS). Dr. Mumcu is married and has two daughters. She enjoys spending time with her family, travelling, and yoga. She currently works at Sultanbeyli State Hospital in Istanbul.



Clinical development of Tie2 positive nucleus pulposus progenitor cell product for low back pain

Daisuke Sakai
Tokai University School of Medicine

Low back pain affects various individuals, from the working population to the locomotive syndrome of the elderly, and its social and economic impact is unignorable. In particular, the intervertebral disc, which is closely related to low back pain, is a tissue that changes significantly with aging and degeneration, and degeneration of the intervertebral disc leads to the development of herniated disc and various spinal degenerative diseases. Stem/progenitor cells have been isolated from various musculoskeletal tissues. Recently, cells with MSC-like properties have been isolated from degenerate human intervertebral discs, providing support for the presence of mesenchymal progenitors.

We have isolated progenitor cells from human and mouse nucleus pulposus (NP) of the intervertebral discs that are different to adhesive MSCs, able to form spheres similar to neural progenitors. These cells have self-renewal and multipotential characteristics consistent with progenitor cells. These progenitors express Tie2 as a marker that progress toward Tie2+/GD2+ cells, with the subsequent expression of CD24 and CD44 as markers for nucleus pulposus (NP) cells in culture and self-renewal property is then lost. Therefore, cells that express Tie2 may be a novel source of donor NP cells in cell therapy for degenerative disc disease.

In order to develop a cell therapeutic agent derived from Tie2 positive NP cells, we isolated NP cells from young donors who had undergone herniotomy for lumbar disc herniation. Minced NP tissue was macroscopically isolated and tissue was brought into whole tissue organ culture for 2 weeks. Thereafter, tissue was then enzymatically digested and cells were expanded in 2D culture for 2 weeks. Tie2 positivity was checked after harvest and counted. Tie2 positivity, proteoglycan and type II collagen positivity after expansion culture was measured by flow-cytometry.

Tie2 positive NP cells may provide superior outcomes in cell therapy for degenerative disc disease and low back pain compared to other cell products.

Education and Professional Work

Name: Daisuke Sakai Nationality: Japanese

Born: April, 9th, 1973

Address: 1-8-24 Nishikamakura, Kamakura-shi, Kanagawa, Japan, 248-0035

Society Appointments

Japanese Orthopaedic Association

2011-2014, 2017- International Affairs Committee member,

2015-2016 Advisor 2018~ Chairman

2016-2019 Low Back Pain Guideline Committee member

2018- present Lumbar Disc Hernia Guideline Committee member

Japanese Society for Spine Surgery and Related Research

2016-present, International Affairs Committee member Japanese Scoliosis Research Society

2017-present, International Affairs Committee Society

Journal Editorial Appointments

Journal of Orthopaedic Research – Spine 2017- present, Co-Editor-in-Chief

Journal of Orthopaedic Surgery, Official Journal of APOA 2011- present, Basic Science Section Editor

Journal of Orthopaedic Research 2011- present, Editorial Board

Journal of Orthopaedic Science 2010- present, Editorial Board

Scientific Reports

2019- present Editorial Board

Awards

2003 Research Encouragement Award

International Society for the Study of Lumbar Spine (Japan Branch)

2003 Young Researcher Award The Naito Foundation

2004 Research Encouragement Award The Kanagawa Foundation for Intractable Disease

2006 North American Spine Society Best Research Paper Award

2013 Research Recognition Award, The Japanese Orthopaedic Association



Step by Step Technique of Full Endoscopic Trans-oral, C2 Transcorporeal, C2-3 Disc Hernia Fragmentectomy and Spinal Cord Decompression using Spinal Endoscope

Elmer Jose Arevalo Meceda
Chairman, Bicol Brain and Spine Care Center

Disc Hernia in the C2-3 level is very rare at incidence rate of 0.2-0.45%. It presents with high cervical spinal cord compression and myelopathy -radiculopathy which is highly debilitating. To manage patients suffering from this condition, decompression of the spinal cord is required. Due to its rarity, there is no standard of treatment and literature only has case reports and case series where anterior techniques and posterior transdural techniques are elucidated.

I will present a step by step technique of a successful full endoscopic trans-oral, C2 transcorporeal approach in spinal cord decompression using spinal endoscope under continuous saline irrigation and its outcome in a patient where anterior approaches are contraindicated.

Education and Professional Work

neurospineejam@gmail.com; eameceda@uerm.edu.ph,

ejameceda@stlukes.com.ph; mobile: +639178111133

Short Description: Dr. Meceda is a Neurosurgeon, a Minimally Invasive Spine Surgeon,

A Pioneer Endoscopic Spine Surgeon in the Philippines,

Assistant Professor of Neurosciences, UERMMMC, College of Medicine

Chairman of the Bicol Brain and Spine Care Center and a

Visiting Neurosurgery Consultant of the

St. Luke's Medical Center- Global City, Institute of Neurosciences, and Capitol Medical Center, Department of Surgery

Present Positions:

Chairman, Bicol Brain and Spine Care Center (April 2021 to present)

Head, Section of Neurosurgery, Bicol Medical Center (

Assistant Professor, UERMMMC, College of Medicine, Department of Clinical Neurosciences

Consultant Neurosurgeon, MIS-Spine

Endoscopic Spine Surgery Specialist

Academy of Filipino Neurosurgeons Inc, Treasurer, January 2021- January 2022

Academy of Filipino Neurosurgeons Inc., Board Member, January 2020 to present

Philippine Spine Society, Member, MISS Research Group 2017 to present

Board Member, Asian Congress of Minimally Invasive Spine Surgery, 2019 to present

Philippine Representative to Asian Congress of MISS, 2018

Board Member, ASEAN Minimally Invasive Spine Surgery and Techniques Congress, 2016 to present

Philippine Representative to ASEANMISSST, 2016

Scientific Committee Chairman, 5th ASEAN Minimally Invasive Spine Surgery and Techniques 2019

Board Member, 12th – 14th MISS Summit Forum 2019 to present, Aichi, Japan

Executive Presidium, International Society of Endoscopic Spine Surgery (ISESS), 2017 to present

International Faculty and Investigator, trans-Sacral/ trans-Foraminal Epiduroscopic Surgery

tSELD Study Group, Good Doctor Teun Teun Hospital/AICHI Spine Hospital (December 2015 to present)



Minimum Invasive Posterior Lumbar Interbody Fusion (PLIF) using TASS (Trans-articular surface screw) for Isthmic Spondylolisthesis

Hidetomi Terai

Dept. of Orthopaedic Surgery,
Osaka City University Graduate School of Medicine

Since 2014, we have performed minimum invasive posterior interbody fusion (PLIF) for isthmic spondylolisthesis using originally developed screw insertion technique “Trans-articular surface screw (TASS) for S1” combined with cortical bone trajectory (CBT) screwing for L5.

The procedure enables a proficient surgeon to perform L5/S PLIF with 5cm diameter single skin incision. Bilateral PLIF is performed using 3-dimensional porous titanium cage (Vusion Ti 3D, Japan Medical Dynamic Marketing) after Gill’s procedure. After PLIF, CBT screw of L5 is inserted from L5 pedicle stump’s surface, which becomes visible after PLIF. The direction of CBT screw is from medial to lateral and from caudal to cranial. Screw tip should locate within the vertebral body. The average screw width and length are 5.5 mm and 35 mm, respectively. After L5 screw insertion, TASS is performed. The entry point of TASS is one third from the lateral border and one third cranial from the caudal border of the facet in the superior articular process of S1. The screw tip should toward promontorium in the sagittal plane. The screw length should be enough long to reach the anterior vertebral wall but not be longer to penetrate it (35-40 mm in most cases). The screw width should be as wide as possible unless otherwise breaching medial wall of S1 pedicle (6.5-7.5 mm). The screw purchase pathway and screw length should be directly examined with feeler under fluoroscope after drilling and tapping.

Practical technique of this minimum invasive PLIF with the above-mentioned technique for patients with L5 isthmic spondylolisthesis will be introduced in this VIDEO presentation.

Education and Professional Work

PERSONAL INFORMATION

Date of Birth: October 24, 1970

Place of Birth: Osaka, Japan

Citizenship: Japanese

Professional Address: Department of Orthopaedic Surgery
Osaka city University Graduate School of medicine

HONORS AND AWARDS

1999 Research award from Nakatomi Health and Wellness Organization

2007 Research award from Chiyoda Health and Wellness Organization

2009 Research award from Japan Foundation for aging and health

2019 Best presentation award in 26th meeting of JPSTSS (Japan Society for the Surgical Technique for Spine and Spinal Nerves)

EDITORIAL ACTIVITIES

Ad Hoc reviewer: Journal of Orthopaedic Science Acta Biomaterial Biomaterials Bone

Journal of Biomedical and material research

Journal of Orthopaedic Surgery and Research etc...

MAJOR CLINICAL AND RESEARCH INTERESTS

Spine surgery (Scoliosis, Pediatric, Degenerative, Minimum invasive),

Regenerative medicine, Bone graft substitute



Has it become easier to learn how to perform full-endoscopic spine surgery?: Effectiveness of the Endoscopic Surgical Skill Qualification system in fully- endoscopic lumbar discectomy.

Hiroki Yoshimatsu, Yasushi Miura, Shu Nakamura, Motohide Shibayama, Zenya Ito, Minoru Yamada, Naoto Hoshi, Keita Kuraishi, Kenzo Shimizu, Guanghua Li, Fujio Ito

Department of Spine Surgery, Aichi Spine Hospital, Japan

【Background】 In 2004, the Endoscopic Surgical Skill Qualification (ESSQ) system for the spine of the Japanese Orthopaedic Association (JOA) was established ahead of other countries in order to facilitate the sound spread and progress of endoscopic spine surgery in Japan. In 2013, the ESSQ system of fully-endoscopic lumbar discectomy (FELD) was started.

【Purpose】 This study aimed to compare the process for acquisition of FELD between surgeons who started the FELD procedure before 2013 and surgeons who started it after 2013. We examined the efficacy of the ESSQ system in FELD and the present problems.

【Materials and Methods】 We performed a questionnaire survey on the process of the acquisition of FELD. Nine endoscopic spine surgeons (6 certified endoscopic spine surgeons and 3 non-certified endoscopic spine surgeons) were targeted. The study population was divided into two groups, the first period and the second period, according to the time that the procedure was introduced in fully-endoscopic spine surgery (FESS), and the two groups were compared.

【Results】 There was a high incidence of complications in the early stage (from the first operation to 30 cases) of the introduction of FELD. There were 7 Drs that required revision surgery due to a lack of decompression, 6 Drs in dura tear and 5 Drs that required a change in the planned operation method based on the intraoperative findings. The types of complications in the early stage were different between two groups. In the first group, there was breakage of operation instruments, convulsive seizure and intraoperative neck pain. In the second group, there exiting nerve root injury and dura tear were frequent. There was an important difference in the contents of the education that the operators received. In the second group, the operators participated in various training sessions and received coaching on endoscopic spine surgery from a supervisor. All members pointed out the effectiveness of the ESSQ system in FELD.

【Discussion】 To minimize the occurrence of complications, a committee of the ESSQ system in the JOA emphasizes the importance of the continuation of instructional activity and the establishment of an education system. In this study, following the introduction of the ESSQ system, the enhancement and diversification of the contents of education were seen and the establishment of the instruction system advanced. As a result, it is now easier to learn FESS. However, the complications observed in the early stage of its introduction have not been solved. In fact, some of the complications that accompanied the expansion of the indications have increased. These results show that further enhancement of education in patient selection, operation technique and other areas, is required to achieve safe FESS.

Education and Professional Work

Education and Professional Work

1996 M.D., Kurume University School of Medicine

2001 Ph.D.(Doctorate of Medical Science), Kurume University, Department of Orthopaedic Surgery

2001 Medical Staff of Orthopaedic Surgery in Kurume University

2006 Manager of Spine of Orthopaedic Surgery in St. Mary's Hospital

2011 Vice-Head of Medical Office of Orthopaedic Surgery in Kurume University

2013 Head of Medical Office of Orthopaedic Surgery in Kurume University

2015 Chief physician of Spine and Spinal Cord Center in Omigawa General Hospital

2017 Spine fellow in Pohang Wooridul hospital, Korea

2017 Chief of Spine Surgery Division in Aichi Spine hospital



Effect of Dorsal Root Ganglion Retraction in Endoscopic Lumbar Decompressive Surgery for Foraminal Pathology: A Retrospective Cohort Study of Interlaminar Contralateral Endoscopic Lumbar Foraminotomy and Discectomy versus Transforaminal Endoscopic Lumbar Foraminotomy and Discectomy

Hyeun Sung Kim, Ji Yeon Kim, Pang Hung Wu, Il-Tae Jang

Department of Neurosurgery, Nanoori Gangnam Hospital, Seoul, Republic of Korea

OBJECTIVE: Postoperative dysesthesia (POD) is a common complication in surgery involving foraminal diseases, including lumbar foraminal or extraforaminal herniated nucleus pulposus (HNP). Minimal dorsal root ganglion (DRG) retraction is key to preventing POD. We compared the clinical results, safety, and efficacy between the paraspinous transforaminal approach requiring DRG retraction and the interlaminar contralateral approach without DRG retraction for foraminal and extraforaminal diseases.

METHODS: A retrospective cohort study was performed of 50 patients who underwent uniportal transforaminal endoscopic lumbar foraminotomy and discectomy (TELD) and 50 patients who underwent anuniportal interlaminar contralateral endoscopic lumbar foraminotomy and discectomy (ICELF) because of lumbar foraminal HNP. The operated levels, combined degenerative diseases, postoperative complications, and POD were analyzed. The visual analog scale (VAS) pain scores modified Oswestry Disability Index, and MacNab criteria for evaluating pain disability and response were analyzed.

RESULTS: In the ICELF group (total, n [7, 14%), there were 5 (10%) and 2 (4%) patients with POD grade 1 and 2, respectively. In the TELD group (total, n [13, 26%), there were 7 (14%), 5 (10%), and 1 (2%) patients with POD grade 1, 2, and 3, respectively. The overall occurrence rate of grade 2 and greater POD was higher in the TELD group (n [6, 12%) than in the ICELF group (n [2, 4%). In the ICELF group, 3 of 9 patients (33%) with combined canal structure deforming diseases had POD, of whom none had POD of grade 2 and greater. In the TELD group, 4 of 7 patients (57%) with combined canal structure deforming diseases had POD, of whom all had POD of grade 2 and greater. Two surgical groups showed favorable clinical outcomes with the visual analog scale, Oswestry Disability Index, and MacNab criteria.

CONCLUSIONS: Both TELD and ICELF were found to treat foraminal or extraforaminal HNP with good clinical outcomes. ICELF might have a lower POD rate in complicated cases such as adjacent segment disease, degenerative spondylolisthesis, and isthmic spondylolisthesis. This surgical procedure could be an alternative in complicated cases or in patients with an anatomically limited L5-S1 level. However, the procedure is technically challenging to perform.

Education and Professional Work

HYEUN SUNG KIM, MD, PhD (Dr. Harrison Kim)

(Neurosurgery Specialist / Director of the Nanoori Hospital Gangnam)

A Section Editor of World Neurosurgery / Neurospine / IJSS / Associate Editor of BMC Musculoskeletal Disorders / Academic Editor of Medicine / Guest Editor of Brain Sciences

Medical College of Chosun University, Gwangju, South Korea (1994~1999)

neurospinekim@gmail.com, neuros@hanmail.net, <https://www.facebook.com/hyeunsung.kim>

Major Career

2018 Parviz Kambin Award (Best Award of the Endoscopic Spine Surgery)

2019 NASS annual meeting: Endoscopic Spine Surgery Workshop and Symposium Director

2021 KOSESS (Korean Research Society of Endoscopic Spine Surgery) President

Editor: World Neurosurgery / Neurospine / IJSS / BMC Musculoskeletal Disorders / Medicine / JMISST



The role of unilateral biportal endoscopy (UBE, BESS, dualPortal) for cervical degenerative pathologies

Javier Quillo olvera
Hospital H+, Querétaro

Abstract

Minimally invasive spine surgery (MISS) in all its variants has been shown to offer clinical and radiological outcomes similar to those obtained with conventional techniques with the added value of a lower collateral effect associated with the procedure. This is helpful since the patient has favorable short-term clinical results, which leads to a shorter recovery time, especially for a quick mobilization out of bed after spinal surgery.

Among the minimally invasive spine techniques are water-based endoscopy, uniportal endoscopy or full-endoscopy, and biportal endoscopy. Both are techniques that depend on continuous saline irrigation to appreciate the anatomy. In addition, both procedures are target-addressed, which means a high specificity of execution. This results in minor trauma to paraspinous tissues, less injury to stabilizing structures, and decreased procedure-related risks. However, uniportal endoscopic techniques require equipment that can be expensive for some regions, a steeper learning curve for some surgeons, and some limitation in the surgical field regarding the use of surgical tools.

Biportal endoscopic surgery aims to overcome the uniportal issues by offering more comfort with a more range of freedom of the surgical instruments since they have an independent channel from the endoscope. Similar visualization and a minor trauma for paraspinous tissues can be obtained during its execution with slight differences compared to uniportal procedures.

Biportal endoscopic surgery has evolved, and diverse KOLs worldwide have reported advanced techniques to treat cervical degenerative pathologies, such as herniated discs, foraminal stenosis, and central stenosis in patients with spondylotic myelopathy. Precision and specificity are required in these pathologies, and biportal endoscopic technique is an acceptable treatment option for covering these goals.

This represents a constant evolution and adaptation of lumbar techniques to other spine regions. Finally, this talk gives an overview of biportal endoscopic techniques for degenerative pathologies of the cervical spine.

Education and Professional Work

Javier Quillo-Olvera M.D.

Spinal Neurosurgeon and Neurology Professor.

Anahuac University, School of Medicine, Hospital H+, Querétaro City, México.

Head of The Brain and Spine Care, Minimally Invasive Spine Surgery Group, Hospital H+ Queretaro.

Endoscopy Faculty for AOSpine.

Member of the Academic Committee of Inter-American Minimally Invasive Spine Surgery Society (SICMI).

Member of Mexican Association of Spine Surgeons (AMCICO).



Preliminary Technical Report; Endoscopic Extreme TLIF (eXTLIF) for Large Cage

Jin Hwa Eum , Dong Hwa Hoe

Burjeel Royal Hospital, UAE, Seoul Bumin Hospital, Korea

Introduction:

Mini-TLIF has allowed for a minimally invasive method to treat degenerative lumbar spinal pathologies. Endoscopic interbody fusion techniques are used frequently right now. One of the disadvantages of the mini-TLIF and endoscopic fusion surgeries is using a relatively small cage with a small fusion bed compared to other large XLIF or OLIF cages. We used a OLIF cage instead of a small TLIF cage for a larger size fusion bed and spacer under the endoscopic extreme TLIF procedure.

Materials and Methods:

8 patients who underwent endoscopic extreme TLIF from December 2019 to January 2020 were included in this study. Clinical outcomes were assessed using a visual analogue scale (VAS). Whole and segmental lordotic angle were compared postoperatively.

Images and clinical findings that include surgical techniques and related complications were analyzed.

Results:

The mean age of the patients (4 men, 3 women) was 65.5 years old. The mean VAS score was improved. The Cobb's angle of whole and segmental lumbar lordotic angle were improved except one patient. One patient resulted with transient nerve root irritation, but there were no significant neurologic deteriorations or major complications were noted.

Conclusion:

The endoscopic extreme TLIF (eXTLIF) procedure provides us a larger interbody fusion bed and spacer compared to those of TLIF surgery. Further long-term study is required.

Education and Professional Work

JinHwaEum,M.D.

South Korea, +82 10 7687 2357 jinspsp@hanmail.net

Leadership, Membership, Presentations

Presenter, "Translaminar Endoscopic Discectomy"

The 4th Biennial Korea-Japan Conference on Spinal Surgery, 2003.

1st presentation about UBE surgery.

Exchange Visitor, Albert Einstein College of Medicine of Yeshiva University, New York, 1994 – 1995.

Member, International Chapter, NASS (North American Spine Society)

Volunteer & Community Work

Mentor for new medical doctors entering spinal residency

Active in hospital volunteer programs

References Available Upon Request



Anterior Endoscopic Cervical Unco-Foraminotomy

Jun Ho Lee

Dept of Neurosurgery Kyung Hee University Medical Centre
Seoul 02447 Rep of Korea

ABSTRACT

Endoscopic anterior cervical unco-foraminotomy is a general encompassing term for surgeries performed in our practice for two major purposes: the first specific purpose is merely to enlarge a narrowed neural foramen, and the second purpose is its use as a conduit to remove surgically treated pathological entities such as herniated soft disc fragments, bone spurs. This MISS cervical procedure has often been entitled as “anterior cervical foraminoplasty” because the narrowed neural foramen, which most often is narrowed due to bone spurs along the medial foraminal wall, is remodeled to restore normal caliber. The endoscopic ventral uncinated process resective decompression (unco-foraminotomy) can help to ameliorate arm pain more promptly in cervical radiculopathy patients with stenotic neural foramens. However, this non-fusing MISS cervical decompressive technique has been fraught with biomechanical issues especially in terms of cervical stability maintenance.

An investigation regarding the effect of uncinated process resection (UPR) during the standard ACDF has revealed that if the sum of UPR is $\geq 38\%$, the possibility of subsidence increases significantly. Moreover, following unilateral unco-foraminotomy, a significant alteration in mobility of the segment is found, especially during lateral bending and axial rotation. Also, according to the analysis of the biomechanical Influences of trans corporeal tunnels on C4 vertebra under physical compressive load under flexion movement using a finite element analysis, trans corporeal tunnel in C4 vertebrae without endplate excision should be limited with diameter of 6 mm, and a tunnel diameter >10 mm, excision of the endplate >8 mm, and excision of the center side of the endplate has been recommended to be avoided.

Further investigations of the natural course of disc degeneration and the impact on mobility after unco-foraminotomy are needed.

Education and Professional Work

PERSONAL INFORMATION

Professor

Department of Neurosurgery, Spine Section Kyung Hee University Medical Centre

23 Kyung Hee Dae Ro, Dong Dae Mun-Gu Seoul, South KOREA

Post Code 02447 Tel: +82-2-958-8405 Fax: +82-2-958-8385 E-mail: moo9924@khu.ac.kr

MEMBERSHIP


International member, Tier I, Member's Feedback Committee, North American Spine Society

Member & International Faculty, AOSpine Davos course, Asia-Pacific & North America

Member & Executer, Walter E Dandy Neurosurgical Society

Member, Korean Neurosurgical Society

Member, Korean Spine Neurosurgical Society



Push To The Limit, Revision Spine Surgeries Using The UBE Technique

Jwo-Luen Pao

Far-Eastern Memorial Hospital, New Taipei,

【Abstract】

As spine surgeries were widely performed, an increasing number of patients required revision surgeries due to neglected pathologies, newly developed pathologies, or complications in previous surgeries.

From Sept 2018 to Dec 2020, 76 patients received revision surgeries in the lumbar spines using biportal endoscopic techniques. They were 36 males and 40 females with an average age of 68.0 (ranged 36 ~ 87). The indications for revision included adjacent segment disease (ASD) following spine fusions in 31 patients, recurrent disc herniation in 11 patients, neglected foramen stenosis and far-out syndrome in 8 patients, re-stenosis in 8 patients, newly developed stenosis in 5 patients, post-decompression instability in 5 patients, inadequate decompression 3 patients, and implants related complication (interbody fusion cages, interspinous devices, and transpedicle screws) in 3 patients. Revisions were performed on previously operated levels in 44 patients and new levels in 32 patients. Three major biportal endoscopic approaches were used: interlaminar laminotomy in 30 patients, paraspinous foraminal decompression in 26 patients, and revision biportal endoscopic transforaminal lumbar interbody fusion in 20 patients.

The treatment results were very encouraging with significant relief of neurological symptoms, sciatica, and low back pain in most of the patients. With minimal blood loss and post-operative wound pain, the average hospital stay was only 3.2 days for decompression alone and 4.8 days revision fusion. Most of the patients start to ambulate on the 1st or 2nd post-operative day. Follow-up MRI showed adequate decompression in most of the patients with minimal new soft tissue injury. Complications including 5 tiny dural tears were treated conservatively. Secondary surgeries were required in 3 patients due to inadequate decompression and post-decompression segmental instability. According the MacNab criteria, 66 patients (86.8%) had good and excellent results, 8 patients (10.5%) had fair results, and 2 patients (2.6%) had poor results.

Using biportal endoscopic techniques in revision spine surgeries is a revolutionary advancement. In selected cases, the revision surgeries could be done successfully with small surgical wounds, minimal soft tissue injury and blood loss. Removal or revision of the old implants was only indicated in patients who required extension of the fusion segments.

Education and Professional Work

Jwo-Luen Pao, MD

Chief of Spine Surgery & Clinical Assistant Professor

Chief of Department of Orthopedic Surgery

Far Eastern Memorial Hospital, New Taipei, Taiwan

21, 2nd Sec., Nanya South Road, Banqiao District, New Taipei, 22060 Taiwan

Tel: +886-2-8966-7000 ext 2888; Fax: +886-2-77282894

Website: <http://www.iSpineCare.com>

E-mail: jwoluenpao@gmail.com; drpao@ispinecare.com

Positions in Medical Society

Board member of the Pan Asian Society for Minimally Invasive Spine Surgery (PASMIS)

Board member of the Taiwan Society for Minimally Invasive Spine Surgery (TSMIS)

President of the Taiwan Society for Endoscopic Spine Surgery 2022 (TSESS)

National and Regional Faculty of the AOSpine Foundation

Member of the Taiwan Spine Society

Member of the Taiwan Orthopedic Association

Member of North American Spine Society (NASS)



FEASIBILITY OF DEEP LEARNING ALGORITHMS FOR REPORTING IN ROUTINE SPINE MAGNETIC RESONANCE IMAGING

1Kai-Uwe Lewandrowski

2Naru Muraleedharan, 3Steven Allen Eddy,

Staff Orthopaedic Spine Surgeon Center for Advanced Spine Care of Southern Arizona and Surgical Institute of Tucson

Department of Orthopaedics, Fundacion Universitaria Sanitas

ABSTRACT

Background: Artificial intelligence is gaining traction in automated medical imaging analysis. Development of more accurate MRI predictors of successful clinical outcomes is necessary to define indications for surgery better, improve clinical outcomes with targeted minimally invasive and endoscopic procedures, realize cost savings unneeded spine care.

Objective: To demonstrate the ability for deep learning neural network models to identify features in Magnetic Resonance Imaging (MRI) DICOM data sets that represent varying intensities or severities of common spinal pathologies and injuries and to demonstrate the feasibility of generating automated verbal MRI reports comparable to those produced by reading radiologists.

Methods: Three-dimensional anatomical model of the lumbar spine was fitted to each of the patient's MRIs by a team of technicians. MRI T1, T2, sagittal, axial, and transverse reconstruction image series were used to train segmentation models by the intersection of the 3D model through these image sequences. Class definitions were extracted from the radiologist report for the central canal – (0) no disc bulge/protrusion/canal stenosis, (1) disc bulge without canal stenosis, (2) disc bulge resulting in canal stenosis, and (3) disc herniation/protrusion/extrusion resulting in canal stenosis. For both neural foramina were assessed with either – (0) neural foraminal stenosis absent, or (1) neural foramina are stenosis present. Reporting criteria for the pathologies at each disc level and, when available, the grading of severity were extracted, and Natural Language Processing (NLP) model was used to generate a verbal and written report.

Results: The initial prediction validation of the implemented deep learning algorithm was done on 20% of the data-set, which was not used for AI training. Out of the 17,800 total disc locations for which MRI images and radiology reports were available, 14,720 were used to train the model, and 3,560 were used to validate against. The convergence of validation accuracy achieved with the deep learning algorithm for the foraminal stenosis detector was 81% (sensitivity 72.4.4%, specificity 83.1%) after 25 complete iterations through the entire training data-set (epoch). The accuracy for the central stenosis detector was 86.2 % (sensitivity 91.1%, specificity 82.5%), and 85.2% (sensitivity 81.8%, specificity 87.4%) for the disc herniation detector.

Conclusions: Deep learning algorithms may be used for routine reporting in spine magnetic resonance imaging. There was a minimal disparity between accuracy, sensitivity, and specificity, indicating that the data was not overfitted to the training set. The authors concluded that variability in the training data tends to reduce over-fitting and over-training as the deep neural network models learn to focus on the common pathologies. In future studies should demonstrate its accuracy and predictive value of favorable clinical outcomes with intervention and surgery.

Education and Professional Work


" He currently is in private practice at the Center For Advanced Spinal Care of Southern Arizona in Tucson and the Surgical Institute of Tucson.

" He is a Clinical Assistant Professor at the University of Arizona in Tucson, and visiting Professor at the Universidade de Estado do Rio de Janeiro, Gaffree Gingle.

" He has authored over 68 papers, over 40 book chapters, 10 posters presentations and edited 13 text books. He holds 6 patents. He has had numerous national and international speaking engagements.

" In his practice in Tucson, he focuses on minimally invasive spinal surgery to improve clinical outcomes while minimizing the impact of spinal surgery. He is an expert on outpatient endoscopic spinal surgery procedures and has published a best-selling text book on it which has been translated in other languages as well.

" In his spare time, Dr. Lewandrowski loves to travel, he speaks 7 languages, and has multiple hobbies including piano, cooking, sailing, and bee keeping.



Clinical Update on Minimally Invasive Spinal Treatment (MIST)

Ken Ishii

Department of Orthopaedic Surgery, School of Medicine,
International University of Health and Welfare (IUHW)

Various minimally invasive surgery (MIS) techniques are gaining popularity due to an aging population and the needs of patients with spinal disorders. MIS is a widely developing field that has the potential to decrease surgical risks and improve recovery, compared with traditional open spinal surgery. MIS was initially applied for indications of spinal decompression surgeries. The percutaneous nucleotomy technique, which was reported by Hijikata in 1975, developed to full-endoscopic surgery (FES). The micro endoscopic discectomy (MED) procedure was established in 1997. To date, these endoscopic surgeries have been spread and applied for various surgical procedures including laminectomy, laminoplasty, and foraminotomy, etc.

During the last decade, MIS techniques have also been used for spinal fusion or stabilization techniques, which are classified as minimally invasive spine stabilization (MIS_t) procedures including percutaneous pedicle screws (PPS) fixation, lateral lumbar interbody fusion (XLIF, OLIF, ACR), balloon kyphoplasty (BKP), percutaneous vertebroplasty, interspinous process motion-sparing implant, cortical bone trajectory, cervical total disc replacement, etc. In particular, procedures that PPS are practiced widely, such as MIS-transforaminal lumbar interbody fusion (TLIF) and MIS long fixation. The indications of MIS-fusion with PPS insertion technique include various lumbar degenerative diseases, isthmic spondylolisthesis, burst fractures, spinal metastasis, spinal deformity, as well as spinal infection. These MIS techniques typically provide preservation of paraspinal musculature, less blood loss, shorter operative time, less postoperative pain, lower infection rate, more cost-effective, compared to traditional open techniques.

In this lecture, I will introduce the efficacies and benefits of PPS fixation and new aspects related to LIF combined with PPS procedure. The spinal surgery has recently experienced much technological innovation. I will also mention that the computer-assisted navigation and augmented reality demonstrate significant advantages in complicated and intractable MIS cases.

Education and Professional Work

Professor and Chairman,
852 Hatakeda, Narita City, Chiba, 286-8520, Japan
1-4-3, Mita, Minato-ku, Tokyo 108-8329 Japan
Birthplace Tokyo, Japan
TEL +81-3-3451-8121, FAX +81+3-3454-0067, Email kenishii88@gmail.com,

HONORS/AWARDS

2004 Grant of The Uehara Memorial Foundation
2006-2008 Grant of The General Insurance Association of Japan
2009 Grant of Japan Orthopaedics and Traumatology Foundation
2009 Asia Traveling fellowship (Japanese Society for Spine Surgery and Related Research) 2009
2010 Cervical Spine Research Society Asia Pacific Section (CSRS-AP) Poster Award 2010
2011 1st Keio Intellectual Property Award 2011
2012 The American Academy of Orthopaedic Surgeons (AAOS) Guest Nation Poster Award 2012
2012 The Japanese Orthopaedic Association Encouragement Award 2012
2015 Cervical Spine Research Society (CSRS) travelling fellowship 2015
2015 Keio Sanshikai Kitajima Award 2015
2015 The 30th Annual Research Meeting of the Japanese Orthopaedic Association Poster Award, etc



Posterior Full Endoscopic Cervical Decompression (P-FECD) for Unilateral Radiculopathy after Anterior Cervical Discectomy and Fusion (ACDF)

Keng-Chang Liu

Buddhist Dalin Tzu Chi General Hospital

【Introduction】

Neurologic symptoms may occur after ACDF because of inadequate decompression, scar adhesion or natural degeneration. The pathologic lesions usually locate on the posterolateral edge of vertebral body. When revisional surgery is indicated, repeated anterior approach would be disturbed by the adhesive scar and previous interbody fusion, and associated with high morbidity. Posterior approach should be convenient for decompression, but traumatization to posterior structure is the main concern. The purpose of this study is to present the potential of the P-FECD as a good option for revisional surgery after ACDF.

【Materials and Methods】

From Jan. 2020 to Dec. 2021, 4 patients (2 male and 2 female) with a mean age of 49 (range, 42 to 62) years underwent P-FECD for unilateral radicular symptoms after ACDF. Residual neurologic symptoms occurred in 1 patient, recurrent in 2, and contralateral side symptoms in 1. P-FECD was performed in all 4 patients.

【Results】

After P-FECD, all 4 patients had significant improvement in neurologic symptoms, and obtained excellent results. There were no intraoperative or postoperative complications. The average hospital stay was 2 days.

【Discussion】

The main lesion for the failed ACDF usually is the posterolateral osteophytosis. P-FECD as a revisional procedure after ACDF has several advantages: (1) approach is not interfered with scar or previous fusion, (2) adequate posterior decompression can be achieved with posterior structure minimally traumatized, (3) segmental stability is preserved and unnecessary instrumentation can be prevented, and (4) complications related to repeated anterior approach can be avoided.

【Conclusions】

This study shows P-FECD is a good option of revisional surgery for unilateral radiculopathy after ACDF.

Education and Professional Work

Nationality: Taiwan

Current Postition :

Director, Division of Spine Surgery, Department of Orthopedics, Dalin Tzu Chi General Hospital, Buddhist Tzu Chi Medical Foundation, Taiwan

Educational Background :

Department of Medicine, National Cheng Kung University, Tainan, Taiwan

Department of Orthopedic Surgery, National Cheng Kung University, Taiwan

Current Title:

1. Director, Division of Spine Surgery, Department of Orthopedics, Buddhist Dalin Tzu Chi General Hospital, Taiwan

2. Assistant Professor, School of Medicine, Tzu chi University, Taiwan

Work Performance :

1. Member of Taiwan orthopedic association

2. Member of Taiwan Spine Society

3. Member of Taiwan Society of Minimally Invasive Spine Surgery

4. Board member of Pacific Asian Society of Minimally Invasive Spine Surgery (Representative of Taiwan)

5. Board member of International Society of Endoscopic Spine Surgery (Representative of Taiwan)

6. Board member of Taiwan society of endoscopic spine surgery

E Mail:

kengchangliu@gmail.com

kcliu@tzuchi.com.tw



Versatility of Full Endoscopic surgery for lumbar foraminal and extraforaminal lesions

Kuniyoshi Tsuchiya

Department of Orthopaedics, JCHO Kyushu Hospital

Lumbar extraforaminal lesions are generally considered difficult to treat for two reasons: their diagnosis and their surgical difficulties.

In the diagnosis of lumbar extraforaminal lesion, MRI findings is of great importance. In this point, some typical findings are reported. Those are horizontal directional change of the pathway and tapering or rupture of nerve root signals. Far lateral syndrome should be also addressed especially on L5/S1 level.

Double crush lesions, in which single nerve root is compressed at two different areas along its pathway can't be treated by single approach even with FESS.

Different from double crush, multiple roots involvement is sometimes seen in lumbar pathological condition.

When treating multiple roots involvement at the same level, fusion surgery had been the gold standard for a long time.

Full endoscopic spine surgery (FESS) can be one of the alternatives for fusion surgery.

Single-side lateral recess stenosis can be treated from outside of the foramen and thus decompression of multiple roots become possible with single approach using FESS. Foraminal area is also able to be reached from outside of the foramen and it is an exclusive advantage of FESS.

There is another advantage. Surgical field for extraforaminal lesions tends to be bloody because of the abundance of small vessels. Perfusion used in FESS serves to keep visual field clear with hydrostatic pressure.

On the other hand, bleeding will put serious effect on vision and massive bleeding makes it impossible to continue the procedures. Thus, tight control of bleeding, especially of small arteries around the foramen is especially important in FESS surgery.

All the compressive lesions around single foramen, including far lateral lesion can be treated successfully from single approach with FESS.

In this talk, general management and tips for single portal surgery of lumbar extraforaminal lesions will be discussed.

Education and Professional Work

Name: Kuniyoshi Tsuchiya M.D., Ph.D.

Director, Department of Orthopaedic Surgery and Chief Spine Surgeon
JCHO Kyushu Hospital

1980-1986: Kyushu University, school of medicine (M.D.)

Graduate school of medicine, Kyushu University (Ph.D.)

LICENSES/CERTIFICATION

2010- : Board certified surgeon of Microendoscopic Spine Surgery

2016- : Board certified surgeon of Full Endoscopic Spine Surgery

Activities:

2012-: Delegate: Japanese Spinal Instrumentation Society

2018-: Delegate: AO spine Japan

2019-: Editorial Committee: guideline for lumbar canal stenosis



ENDOSCOPIC FUSION KLIF UBE-ENDO TLIF

Malcolm Pestonji

Professor Mgm University Kamothe Navi Mumbai

Abstract

Endoscopic spine fusion is now a reality

Trans facetal lumbar interbody fusion thru the kamin's triangle has been developed as an indirect decompression technique being a viable alternative technique to Olif and Alif surgeries

avoiding all the morbidity and complications associated with the above procedures also with the advantage of being able to do L5 S1 fusions all under local anaesthesia with patient awake and aware doing his own Neuromonitoring as a distinct advantage

Alternatively the development of unilateral bi portal Endoscopy as an effective tool for endoscopic fusion especially in cases of redo spine surgeries and also under awake sensory epidural anaesthesia has augmented the armamentarium of endoscopic spine surgeons to evolve in dealing with all degenerative spine pathologies combining all posterior pathologies with anterior visualised end plate preparation giving both the benefits of direct and indirect decompression

The era of spine endoscopy has truly awakened

Education and Professional Work

Dr Malcolm D Pestonji MS Ortho, D Ortho Mob: +91 9326471376 Orthopaedic Spine Surgeon ,Regd no 64209
Off : 0250-2334780 Golden Park Hospital Res: 0250-2334992 Vasai (West)

Current Attachments

Orthopedic Endoscopic Spine Surgeon Golden Park Hospital Vasai. Honorary Professor of Endoscopic Spine Surgery MGM University of Health Science, Navi Mumbai, Kamothe. Honorary Professor of Endoscopic Spine Surgery at Bareilly International University & Rohilkand Medical College Hospital, Honorary Endoscopic Spine Surgeon Holy Spirit Hospital Mahakali Andheri (East) Mumbai.

Publications:

Operative Manual-Transforaminal Stitchless Surgery Under Local Anaesthesia for Lumbar Spine, January 2019
Bentham's Contemporary Endoscopic Spine Surgery Cervical Spine

MY VISION

Endoscopic spine surgery has evolved into a safe result oriented surgery the world over. Today due to changing patient demographics there is a higher incidence of canal stenosis in the spondylotic spine along with many other problems. Endoscopic spine surgery is the answer to all those problems. I will be honored to be a faculty at Fortis Hospital Mulund for Endoscopic Spine Surgery



Pain management for top athletes with spinal facet joint disorders and ossification disorders

Masataka Sakane

Department of Orthopedic Surgery & Rehabilitation Tsukuba Gakuen Hospital

It is easy to imagine that repetitive movements due to the competitive characteristics of top athletes exert a mechanical load on the spinal facet joints. However, the diagnosis tends to be delayed and the treatment for chronic pain is not enough for early recovery. We will present some examples of top athletes in various sports who have returned to the competition after performing diagnosis for spinal facet joint pain and ossification disorder, nerve ablation using radio waves, nerve block, and minimally invasive surgery.

Patients: Two baseball pitchers (1 professional, 1 university), 1 professional baseball fielder, 1 sepak takraw player, 1 rugby forward, and 1 hammer thrower. After clinical diagnosis, level diagnosis is performed using selective nerve / facet joint block, and radio wave device (Neurothermo NT500, Abbott Medical) was used. Under local anesthesia and C-arm, we used in an appropriate combination of nerve destruction mode (80 degrees, continuous wave 60 for seconds) and nerve block mode (42 degrees, pulse wave for 120 seconds).

Results: Facet joint disorders and ossification disorders occurred on the opposite side of the pitcher and on the same side of the fielder. Hammer throw (counterclockwise rotation) resulted in a right disc herniated disk and left ossification at the thoracolumbar junction.

After rhizotomy of symptom-reproducible facet joints, upper and lower facet joints, and transverse processes, athletic rehabilitation started about 1 week later, and it was possible to return to competition in 2 months, and the effect lasted for 6-12 months. Athletes with hernia and ossification of the ligamentum flavum underwent surgery under a microscope and returned in 6 months.

Conclusion: Top athletes' facet joint disorders and ligament ossification are affected by competitive characteristics, and high-frequency nerve block treatment is effective for chronic pain for a certain period of time.

Education and Professional Work

Name : Masataka Sakane, MD, PhD

Date of Birth : 16/09.1963

Education : MD 1989 School of Medicine, University of Tsukuba

PhD 1998 University of Tsukuba

Work Experience :

1989 Orthopedic resident, Tsukuba University Hospital

1995 Research fellow, Pittsburgh University

1999 Assistant professor, Ibaraki Prefectural University

2002 Assistant professor, University of Tsukuba

2008 Associate professor, University of Tsukuba

2016 Director, Orthopedic surgery & Rehabilitation, Tsukuba Gakuen Hospital



Let's master the power tool for screw insertion

Masatsune Yamagata
Spine and Low Back Pain Center,
Dept of Orthopaedic Surgery, Chiba Rosai Hospital, Ichihara, Chiba JAPAN

The work of inserting screws and fixing them is widely performed in the world. A screwdriver is used for fixing, but recently power tools are often used. However, only few spine surgeons are experiencing. The field of spine lags behind other fields probably because of the major safety issues. However, with the progress of engineering technology, power tools that can be safely used in the spine field have been developed. I will introduce this power tool. The torque can be maintained at low speed, and it is possible to insert the screw by feeling the manual owl insertion.

Technique: A 3 mm burr is used to create a hole in the posterior elements as the entry point, then a 2.4 mm flexible drill is inserted through the opening burr hole. A power drill can be used safely and slowly. The flexibility of the specially designed 2.4 mm drill bit allows the drill to deflect off hard cortical channels of the pedicle and redirects to preferentially advance down the pedicle channel. Next, a 3 mm blunt-tipped reamer is inserted into the pedicle channel to complete the pedicle cannulation. It may reduce radiation exposure during surgeries.

There are some reports about the accuracy of pedicle screw placement. The powered instruments inserted pedicle screws as accurately as did conventional manual instruments. In addition, the use of power instruments significantly reduced the time needed for inserting pedicle screws.

Conclusions: Power pedicle preparation and screw insertion offers a safe and efficient alternative to manual techniques with the following potential advantages: 1. Less screw toggle, which is associated with stronger screw purchase, 2. Less force applied to the patient's spine, which is desirable from safety, 3. Less muscle exertion for the surgeon, which could reduce overuse injuries of surgeons. 4. Less exposure of radiation during surgery.

Education and Professional Work

Affiliation:

Spine and Low Back Pain Center

Department of Orthopaedic Surgery Chiba Rosai Hospital, Japan Organization of Occupational Health and Safety 2-16, Tatsumidai-Higashi, Ichihara, Chiba, Japan 290-0003

Phone: 81-436-74-1111

1976 Japanese Orthopaedic Association,

(Director 2015-2019, Honorary Member)

1986 Japan Spine Research Society

1990 International Society for the Study of the Lumbar Spine, (Senior Member)

1991 The Japanese Society for Spine Surgery and Related Research

1998 Japan Society for Endoscopic Surgery (Councilor, Special Member)

1999 Japanese Society for the Study of Endoscopic & Minimally Invasive Spine Surgery
(Honorary Member, President 2001)

2001 Pacific and Asian Society of Minimally Invasive Spine Surgery
(Board Member President 2021)

2009 The Japanese Society of Lumbar Spine Disorders
(Director President 2015)

2016 ISESS, International Society of Endoscopic Spine Surgery
(executive committee 2018 Vice President of the 2nd meeting of ISESS)



Endoscopic spine surgery is not equal endoscopic spine surgery - What are the differences and examples of 20 years personal experience -

Michael Schubert

Apex-spine

Background:

Microscopic dorsal lumbar discectomy is still the gold standard treatment for lumbar symptomatic disc herniation. To reduce the complication rate and to eliminate the risks of general anaesthesia, more minimal invasive procedures gain significant interest in patients and spine surgeons. In the last 60 years several other less invasive percutaneous techniques have been developed.

Patient Sample:

Various treatment options from 20 years of endoscopic spinal surgery are shown as examples

Purpose:

Demonstration of the differences of endoscopic spine surgery like interlaminar or transforaminal and as outside-in or insideout technique and personal experiences (ETD).

Methods:

All patients were treated under local anaesthesia and could be discharged the day after surgery. From a lateral approach under X-ray control first the foramen intervertebrale was enlarged and a working cannula and an endoscope was inserted in the ventral part of the spinal canal (TED). The prolapsed or extruded part was removed under endoscopic vision with special forcepses. Different case reports of spine surgery complications or spine problems where endoscopy is the best solution to avoid major surgery

Results:

Endoscopy spine surgery of the thoracal and lumbar spine is possible also for almost all problems in the spinal canal. Like removal of disc herniations, cyst decompression, bone cement dislocation after kyphoplasty, bone fragment removal independent of location in lumbar or thoracic spine.

Conclusion:

The endoscopic transforaminal discectomy (TED) in the out-side-in technique appears to be a safe, effective procedure without significant complications and it seems a good alternative to other endoscopic spine procedures or open microdiscectomy independent of size or location of the herniated disc or presence foraminal stenosis as well

Education and Professional Work

Sciences

Since 1989 More than 14.000 spine surgery's

Since 1989 Around 10.000 endoscopic spine procedures

Since 1989 More than 300 oral presentations in the field of spine

Since 1989 Multiple publications and book chapters

Since 2003 International instructor and visiting professor

Since 2003 More than 400 trained spine surgeons

Since 1990 Member of multiple Spine organizations (NASS, ISASS, ISMISS; IITS; DWG, etc.)



MIS fixation for acute cervical spine injury

Nobuyuki Shimokawa, Hidetoshi Sato, Takafumi Inoue
Department of neurosurgery, Tsukazaki hospital, Hyogo,

Introduction: The application of MIS for cervical spine injury is getting available with the development of surgical peripherals such as intraoperative navigation systems. It is important to carry out MIS fixation safely and reliably.

Aim: To present utility and safety of MIS fixation such as osteosynthesis using O-Arm for cervical spine injuries

Materials and Methods: Since 2017, internal fixation was performed using O-arm for 7 consecutive cases of cervical spine injury. The age ranged from 25 to 72 years, with an average age of 58.7 years. There were 4 males and 3 females. The breakdown of the cervical spine injury was Hangman fracture in 3 cases, hemi-lateral lateral mass fracture in 1 case, Anderson type 3 axial dens fracture in 1 case, C2 vertebral body fracture in 1 case, and hemi-lateral pedicle fracture in 1 case. For reducible fractures, so-called osteosynthesis with screw crossing the fracture line, applying manual compression force to the fracture line was performed. For C2 dens fractures, C1 lateral mass screws and C2 pedicle screws were inserted for minimal invasive fashion.

Results: Bony fusion of the fracture line was obtained in the postoperative image evaluation in all cases. Implant was removed from 4 months to 1 year after obtaining bony fusion of the fracture.

Conclusion: Internal fixation with MIS such as osteosynthesis for acute cervical spinal injury is considered to be one optional technique of the safe and useful surgical techniques.

Education and Professional Work

Personal information

Name: Nobuyuki Shimokawa

Job Title: Head of Spine Center & Chairman of the Department of Neurosurgery

Department: Spine Center & Neurosurgery

Institution: Tsukazaki Hospital, Himeji city, Hyogo, Japan

Country: Japan

Birth: 1965/02/15

E mail: nobu-shimo0215@snow.odn.ne.jp

Academic Interests

2016-2021 Member of WFNS Spine committee

2016-at present Member of The Section on Disorders of the Spine and Peripheral Nerves (DSPN)

2016-at present Member of American Association of Neurological Surgeons (AANS)

2015-at present Member of Cervical Spine Research Society Asia Pacific Section (CSRS-AP) & CSRS-Japan

2015- at present Delegate of AO spine Japan

2015-at present Member of Board Trustee of the Neurospinal Society of Japan (NSJ)

2014 -at present Member of Congress of Neurosurgical Surgeons (CNS)

2013-2015 Inspector of Japanese Society of Spinal Surgery

2012-at present Review Board of *Neurologia medico-chirurgica* (official journal of the Japan Neurosurgical Society)

2012 at present Editorial Board of the Japan Society of Neurotraumatology

2012-at present Editorial Board of the Japan Society of Neurosurgical Emergency

2012 -at present Editorial Board of the Japan Medical Society of Spinal Cord Lesion

2010-at present Member of Board Trustee of the Japan Society for the Study of Surgical Technique for Spine and Spinal Nerves

2010 Board certification as Senior Member (Instructor) and Review Board *SPINAL SURGERY* (official journal of Japanese Society of Spinal Surgery) by Japanese Society of Spinal Surgery

2008 Board certification as Technical Specialist by the Japanese Society of Neuroendoscopy

2006 Board certification as Spinal Surgeon by the Japanese Society of Spinal Surgery

2005 Stroke Specialist certified by the Japan Stroke Society

1997 Board certification as Neurosurgeon by Japan Neurosurgical Society



Outcome of lumbar lateral recess stenosis with PSLD

Nurbyek Baban

Grand-Med hospital, Mongolia

Background:

Lateral recess stenosis is common pathology causing leg pain in the elderly population. Lateral recess stenosis is usually caused by the herniation of the intervertebral disc, hypertrophy of the articular process, and hypertrophy of the ligamentum flavum. In the elderly population usually associated morbidity. Endoscopic decompression, there are advantages in the operation technique, such as reduced traumatization.

For the development of endoscopic spine surgery in Mongolia, we started PSLD at January, 2018.

Percutaneous stenoscopic lumbar decompression (PSLD), optimized for lumbar stenosis is fitted for a surgeon to perform laminectomy, flavectomy, foraminotomy and discectomy unilateral approach and bilateral decompression as well as multi-level decompression.

Methods:

The study was retrospectively conducted with 100 consecutive cases, treated with PSLD under spinal epidural anesthesia between 1th July 2019 to 1th June 2020.

Results:

Mean age of patients was 64.4 ± 5.4 years. Mean symptom duration was 24.1 ± 12.8 months. Postoperative MRI revealed that PSLD increased the canal volume by mean 47.7% of preoperative one at the index segment ($P < 0.001$) and demonstrated that damage in the normal soft tissue including muscles and the extent of removed normal bony tissues appeared minimal. The mean improvements of VAS score and ODI were 4.0 ($P < 0.001$) and 40% ($P < 0.001$) respectively. Macnab outcome grade was 96% of patients. Mean duration of operating times was 32 minutes for unilateral decompression of 1 level and mean hospital stay 2.2 days.

Conclusion:

Decompression of spinal canal stenosis with PSLD not only improved the clinical outcomes but also increased significantly canal volume at each index segments. The main advantage of this new technique in the current study should be a potential of uniportal multi-level procedures under epidural anesthesia minimal damage of normal anatomical structures surrounding the pathology, and short hospitalization.

Education and Professional Work

Personal data:

Family name: Baban First name: Nurbyek

E-mail: nurbeke@yahoo.com Telephone: 976-89117766

Current employer address: Grandmed hospital, Khan-Uul district Ulaanbaatar, Mongolia

Certificate

Mongolian National University of Medical Science, Postgraduate course of Surgery, Surgeon October 2009 – April 2011
Diploma

Mongolian National University of Medical Science, Medical Doctor, Bachelor of Science 2002-2008 Diploma

Bayan –Ulgii, secondary school №1

1992-2002

Professional Interest:

Endoscopic spine surgery



Tubular Retractors as a Minimally Invasive Technique for an Anterior Approach to C1-C2

Rafael Cruz Bundoc
University of the Philippines

Anterior approaches directed to decompress pathologies of C1 and C2 is technically challenging. The conventional open technique involves a lot of possible collateral damage to the anatomy of the oral cavity and nasopharynx in retracting structures to gain our access to the atlanto-axial spine. This lecture describes an alternative minimally invasive procedure to C1 and C2 utilizing tubular retractors over conventional open mouth retractor systems. The lecture will demonstrate how one can use a tubular-endoscope set up to decompress a tuberculous spondylitis at C1 and C2 as a classic example. It will show the simple instruments needed to carry out the procedure in a systematic fashion. It is the aim of this lecture to provide a viable tool when we plan future procedures involving an anterior approach to the atlanto-axial spine.

Education and Professional Work

Major Awards:

Philippine Talent Search for Young Scientist, Gold Award, given by the National Academy of Science and Technology, 1995

TOYM (The Outstanding Young Men) Award in the Field of Medicine, 1997

Joseph Trueta Fellowship Awards, given by the Nuffield Orthopaedic Center, Oxford University, United Kingdom, 1998

Honorary Fellow of the Girdlestone Society, given by the Nuffield Orthopaedic Center, 1999

TOYS (The Outstanding Young Scientist) Award given by National Academy of Science and Technology, 2000

Outstanding Philippine Doctors Award given by the Philippine Jaycees in cooperation with Department of Health, World Health Organization and Philippine Medical Association, 2004

Metrobank Outstanding Teacher for 2005 given by the Metrobank Foundation

Eisenhower Fellow 2008 given by the Eisenhower Fellowship Foundation

Areas of Expertise: Cervical Spine Surgery

Scoliosis and Spine Deformity Surgery

Minimally Invasive Spine Surgery

Design/ Innovation of Instruments

Biomechanical Testing

Anatomical Studies

Prosthetic/Orthotic design

3D Printing surgical applications



Full-endoscopic KLIF and Educational System in Japan

Seiji Yamaya

Department of Orthopaedic Surgery, Sendai Nishitaga Hospital

Background

Full-endoscopic trans-Kambin lumbar interbody fusion (KLIF) was reported in Japan in 2018. It consists of surgical procedures with posterior percutaneous pedicle screw fixation and full-endoscopic anterior interbody fusion using a trans-Kambin approach. It developed for treating degenerative lumbar spondylolisthesis. KLIF can perform indirect decompression like XLIF or OLIF. XLIF or OLIF had some reports about serious complications such as intestinal and major vascular injuries. Such complications are less likely to occur in KLIF due to difference approach. However, KLIF needs the peculiar attention to avoid exiting nerve root injury (ENRI) because the surgical technique based on transforaminal full-endoscopic lumbar discectomy (TELD). ENRI had a reported frequency of 1.0%-8.9% and is known to reduce physical function and overall patient satisfaction after TELD.

The educational system of TELD and KLIF is provided in Tokushima Univ in Japan. Surgeon can master the surgical technique through seminar using the dry model and fresh cadaver. Before performing the KLIF, the surgeon should be familiar with the surgical procedure of TELD under local anesthesia and foraminoplasty outside-in technique to avoid ENRI. I started to perform KLIF after getting this educational system in 2018.

Objectives

There were few reports of KLIF. We studied the clinical outcomes, complications and intervertebral fusion rates of initial 22 patients performed KLIF at one year postoperatively.

Methods

22 cases were performed KLIF by the same surgeon from November 2018 to 2020. The clinical outcomes (JOA score, JOABPEQ, Visual analog scale of low back pain and lower extremity pain) and complications were prospectively evaluated at 1 week, 1, 3, 6 and 12 months postoperatively. The degree of slippage (% slip) was measured on an X-ray before and one year after surgery. The intervertebral fusion rate was evaluated using CT one year after surgery.

Results

All of clinical outcomes improved significantly from as early as 1 month postoperatively compared to preoperatively. There were no serious complications. A transient symptom of exiting nerve root occurred in one case, which improved after one month. The degree of slippage (% slip) improved significantly from 22% before surgery to 8% after surgery, and the interbody bone fusion rate was 91% at one year postoperatively.

Conclusions

KLIF was an excellent minimally invasive procedure with good clinical results, reduction, and high interbody fusion rate (91%). This procedure had no serious complications. In order to spread this surgical technique safely, it is important to develop the educational systems of TELD and KLIF for surgeons.

Education and Professional Work

Education: 2003, *MD degree*, Jichi Medical University.

2014, *PhD degree*, Department of Orthopaedic Surgery, Tohoku University.

Board certification in Japan: 2003 National Board of Medical Doctor. 2011 Approved Orthopaedic Surgeon by Japanese Orthopaedic Association

2015 Board-certified spine surgeon (approved by the board of the Japanese Society for the Spine Surgery and Related Research)

2016 Board-certified endoscopic spine surgeon MED (approved by Japanese Orthopaedic Association)

2021 Board-certified endoscopic spine surgeon FED (approved by Japanese Orthopaedic Association)

Professional and academic employment history

2003 Iwate Prefectural Cyuou Hospital

2010 Department of Orthopaedic Surgery, Tohoku University

2015 Clinical Spine Fellow (MED) of JSSR

Department of Orthopaedic Surgery, Wakayama Medical University

2017 Clinical Spine Fellow (FED) of JSSR

Department of Orthopaedic Surgery, Tokushima University

2017 an assistant professor, Tohoku University

2018 Director of the Center of Endoscopic Spine Surgery, Orthopaedic Surgery, Sendai Nishitaga Hospital



Myogelosis: Skin-to-Muscle Reflex and Effects of Skin-Contact Substances

Shoichi Kokubun

Professor Emeritus, Tohoku University

NHO Sendai Nishitaga Hospital, Sendai, Japan

Myogelosis, hypertonicity of the muscle at rest, causes almost all nonspecific pain.

Pain and neurological hyperalgesia to pinprick are expressed in the skin area of the responsible muscle. The skin areas of muscles are completely different from those of nerve roots (dermatomes) and peripheral nerves.

The human body has a muscle tone regulation system comprising the muscle-to-muscle reflex by muscle contraction, stretch or pressure and the skin-to-muscle reflex by stimulation to the skin. Recently, regarding the latter, it was found that substances such as polyester, polyethylene and silicone generate excitatory inputs and as a result, they heighten the muscle tone and cause pain. In contrast, inhibitory substances such as acrylic fiber, acrylic resin and polyurethane lower the muscle tone and solve pain.

Wearing clothes including a mask and socks and ear pieces containing inhibitory substances instead of excitatory substances is an essential treatment requirement. An effective self-treatment is affixation of adhesive tape with acrylic resin to the skin area of the responsible muscle. (163 words)

Education and Professional Work

Shoichi Kokubun, MD, PhD
Professor Emeritus Tohoku University
Research Center for Spine and Spinal Cord Disorders
NHO Sendai Nishitaga Hospital
2-11-11 Kagitori-Honcho, Taihaku-ku,
Sendai 982-8555, Japan

His major research and clinical activities are pediatric orthopaedics and spine and spinal cord surgery. He is the author of more than 150 original publications in English.

Internationally, the 2nd Triennial Congress of the International Federation of Paediatric Orthopaedic Societies (IFPOS) was a great success under his presidency in Sendai in 2001. He was National Delegate to SICOT (1999-2005), Chief National Delegate to the Asia-Pacific Orthopaedic Association (APOA) (2001-2006), and Chairman of the Spine Section, APOA (2005-2008). He actively contributed to Bone and Joint Decade (2000-2010) as a member of its International Steering Committee from 2003 to 2010. He is now President of APOA (2021-2022). At home, as Congress President, he held the Annual Congress of the Japanese Orthopaedic Association in 2004 and the Annual Meeting of the Japanese Spine Research Society in 2005. In addition, he was President in charge of management of the Japanese Pediatric Orthopaedic Association from 2003 to 2009 and President of Japan Orthopaedics and Traumatology Research Foundation, Inc., Tokyo, Japan from 2007 to 2017. He was given the Award for the Development of the Japanese Orthopaedic Association in 2018.



UBE (Biportal Endoscopic Spine Surgery)

Son, Sang Kyu
Park Weon Wook Hospital

Looking for ways to treat spine better is still in process. Definitely, the UBE (Unilateral Biportal Endoscopy) is one of those pursuits.

I would like to share some of the history related with the efforts made by forerunners in the journey of UBE. Dr. D J De Antoni, an Argentine surgeon, published an article on lumbar discectomy using arthroscopy in 1996. Dr. Abdul Gaffar from Bahrain presented poster on the same surgical technique on AAOS 2001. Dr. Eum, Jin Hwa introduced Dr. Abdul Gaffar to Korean Spine Society in 2001. Dr. Eum, who modified lateral position to prone position and applied the arthroacore® in spine surgery, performed the first case of lumbar discectomy in Korea. Since 2003, Dr. Son, Sang Kyu established UBE basics (anatomy, concepts, instruments) and advanced to perform stenosis and fusion cases for the first time in the world. Dr. Son had held many professional training seminars to spread out this surgical technique and became the 1st. president of UBE research society. Dr. Heo, Dong Hwa has spared no effort to accumulate academic evidence while publishing papers. Prof. Lee, Sung who was the 2nd. President of UBE research Society and Dr. Park, Chun Kun did lots of work to enlist the UBE as the Korean official surgery. The pursuit for UBE development is still underway by the 3rd. president, Dr. Park, Chul Woong and many other young surgeons such as Dr. Park, Man Kyu. So many professors and doctors in KOMISS and KOSESS are behind UBE. Until now, over 100UBE-related papers have been published globally. In about 27 number of countries, the UBE surgery is being performed. Especially, the Turkey, China and India established local UBE Society and train their local spine surgeons to perform UBE surgery.

Following is the short summary on what is UBE. Every endoscopic procedure needs 'working space', but there is no clear pre-existing working space in the spinal posterior approach. The key point of UBE is how to make 'working space'. For the critical purpose, understanding the structure of the spinal anatomy. There is potential space between multifidus muscle and lamina, and interfascicular space between small muscles of multifidus. UBE is the endoscopic procedure being performed while utilizing the potential space to convert 'atraumatic working space'. UBE is a minimally invasive surgery which focuses on saving muscle, not skin incision. UBE also follows the standard surgical principle and techniques as in conventional surgery, with only critical difference of its being performed under fluid-medium.

The 8 basic concepts for UBE can be summarized such as below. Unilateral biportal endoscopy, fluid-medium surgery, triangulation, semi-tubular system at working portal, one-hand surgery, lens inside, lens to be movable (not fixed) and pivot movement of instruments. UBE has nearly same indication as microsurgery and in some diseases such as cervical foraminotomy, L5S1 extra foraminotomy, it shows better result than microsurgery. Still, the following cases are contraindicated such as the high cervical disease, anterior cervical approach, severe OPLL, high grade lumbar spondylolisthesis, severe scoliosis, severe trauma, severe infection, most all tumor etc.

Future agenda for UBE development includes accumulating more evidence, more microscopic surgeons perform the UBE cases along with conversion trend of microscopic surgery to endoscopic surgery as witnessed in other surgical area. Last but not least, the development of UBE till now, technically and instrument-wise, can become the foundation for robotic surgery and AI-based surgical solution.

Education and Professional Work

Son, Sang Kyu., M.D

General Director, Park Weon Wook Hospital in Busan, Korea

Mobile: +82-10-8575-9871

Email: bread0309@hanmail.net

Main Career & Activities

The First President of UBE Research Society (2017-2018)

The First President of Spine Endoscopy Research Society (2019-2020)

(Present) Director for International Exchange, KOMISS

(Present) Director for International Public Relations, KOSESS

(Present) Honorary chairman of Turkish, Indian and Chinese UBE Society

(Present) UBE Global Master, UBE development/training since 2003

(Present) General Director, International UBE Academy, Park Weon Wook Hospital

(Present) Global Reference doctor for EndoSpineMax, UBE Solution Provider

(Present) Chairperson, International Society of Unilateral Biportal Endoscopy (ISUBE)



WHEN TRANSFORAMINAL, WHEN UBE?

Tarik Yazar

Department of Orthopaedics University of Ankara

Almost all procedures in invasive surgery can be performed with UBE. We can do these attempts by creating minimal trauma to the patient.

If it is necessary to reach the middle part of the neural canal, the UBE has the upper hand. Multilevel spinal stenoses, diffuse stenoses are more easily resolved with UBE. Solution of possible complications is easier with UBE.

In UBE it is difficult to reach outside the middle part of the foramen. This requires personal talent and special tools. The ipsilateral side is even more difficult. May require additional extra foraminal intervention.

If there is central stenosis, if it is moderate, if the recesses are good, if it is unilateral, it is better to enter from the lateral. No need to open ligamentum flavum. Better to approach paravertebral.

If deformity and degeneration are together, if there is stenosis on the concave side, if the scoliosis is more than 20 degrees, two-level decompression with paravertebral entry from the concave side is better.

If it is not necessary to go to the middle layer of the disc, it is correct to go transforaminal, if it is subligamentous, it is better to go transforaminal.

Both methods should be included in our surgical armamentarium. From time to time, one of the methods may gain a priority indication. It may be necessary to apply both techniques in the same case, one after the other.


As a result, the spinal endoscopic surgeon must undergo a training that can use both techniques together.

Education and Professional Work

Place of birth
Artvin, Turkey

Date of birth 26th of may 1951
Nationality Turkish

- In 1988, he graduated from Ankara University Faculty of Medicine, Department of Orthopedics and Traumatology. became an Associate Professor.
- In 1988, he received a patent number 28534 for the mechanical spinal system used in the treatment of spine, trauma and deformity diseases, whose research was carried out at the Vienna International Patent Institute, and this mechanical spinal system was produced in our country.
- He became a professor at Ankara University Faculty of Medicine in 2001.



The advantage of DPEL over MED in the access to the spinal neural element

Tatsushi Inoue

Fujita Health University

Endoscopic laminotomy under irrigation is recently gaining increasing popularity. Professor Dezawa had developed his original scope (DPEL) with 6mm working channel, which enables to use 4mm Kerrison rongeur and 4mm-tip drill and to perform speedy bone removal. The DPEL is advantageous over MED in the access to the spinal neural element about ten times, measured by Access Ratio (AR), which was defined as the maximal ratio of the index root to the thecal sac in the operative field.

In this presentation, we also focus on safe detachment technique under water irrigation of the ligamentum flavum from the theca.

Education and Professional Work

PRESENT APPOINTMENT:

Associate Professor

Department of Neurosurgery and

Department of Spine and Spinal Cord Surgery

Fujita Health University

1-98 Dengakugakubo, Kutsukake-cho Toyoake, Aichi 470-1192, JAPAN

MEMBERS IN PROFESSIONAL SOCIETIES:

Japan Neurosurgical Society

Japan Congress of Neurological Surgeons

The Japanese Society of Spine Surgery

The Japanese Society of Skull Base Surgery

Japanese Congress on Surgery for Cerebral Stroke

The Japanese Society for Pediatric Neurosurgery

Congress of Neurological Surgeons (US)

American Association of Neurological Surgeons

American Association of Neurological Surgeons Spine Section

MAIN RESEARCH INTEREST:

Minimally Invasive Spinal Surgery

Skull Base Surgery



Percutaneous Endoscopic Thoracic Discectomy

Tolgay Satana

Op. Dr. Tolgay Satana

Objective:

The modern era of surgical endoscopy was initiated by the introduction of video-assisted endoscopic capabilities in the late 1970s and 1980s.

Arthroscopy for the diagnosis and treatment of knee and shoulder pathologies grew and essentially replaced open techniques. The revolutionary growth of laparoscopic general surgery began in the late 1980s.

Indication:

Endoscopic strategies have been and are being employed predominantly for the treatment of the following conditions: Lumbar, thoracic and cervical disc herniations with radicular symptoms foraminal stenosis with radicular symptoms degenerative facet joint cysts with radicular symptoms
Diagnosis: Pretending Cardilogic, Gastroenterologic symptoms Intestinal complaining, Fake Hearth attacks Medullapathy Spasticity Deep sensorial loose Sensorial disabilities Pain (lower extremity beside intestinal

Method:

Posteriorlateral Thoracic Discectomy along the red arrow for avoidance of trauma to the nerve, spinal cord, plural cavity, the lung and in the costal artery via the "safety zone" Approach for Posterior lateral Thoracic Discectomy under fluoroscopic guidance between the pedicle and rib headline into the safety zone for discectomy Incrementally advanced at a 35? 45-degree angle from the sagittal plain toward the center of the disc Through the "safety zone" between the inter-pedicular line and? the rib head Confirmatory provocative discography to follow

Material:

2014-2021

24 patients were included prospective study

14 females 10 males

Main age 54

Follow up 18 m (range 3-48 months)

Results:

Patients responds are statistically significant improvement in the VAS, SLR test, ODI..

In regarding to quality of life, there was a statistically no significant increment (p

Education and Professional Work

Executive Member of IMLAS since 2000

Secretary of IMLAS Istanbul 2005

Guest Editor in Turkish Journal of Joint Surgery

Active member of Bone and Joint Turkey Osteoporosis and Osteoarthritis congress responsible of Spine section for 9 years.

Member of Turkish Spine Society

Member of Turkish Ortopedic society

Board member of ISMISS and national representative of Turkey since 2005


Chairman of Turkish Chapter of ISLASS

WALA board member

Founder and President of Turkish MISS

Founder and Coordinator of ISMISS Turkey 2003-14

President of World Federation miss Congress in Istanbul and board member



Thoracic Disc Herniation: An Extended Indication for Full-Endoscopic Spine Surgery

Verapan Kuansongtham, Withawin Kesornsak
Bumrungrad International Hospital

Background

Symptomatic herniated thoracic disc (HTDs) account for only 0.15-1.8% of all intervertebral disc abnormalities treated surgically. Surgical approaches include open thoracotomy and fusion, video-assisted thoracotomy and discectomy and posterior decompression with or without fusion. Full-endoscopic spine surgery has become more popular in recent years. It offers less traumatization and improves early recovery while showing comparable outcomes to the standard operations. In this presentation we present 2 clinical experience of thoracic disc herniation treated successfully with endoscopic approach.

Main Idea

Unlike lower lumbar spine that the existing natural corridor is usually sufficient to pass the endoscope directly to the pathology without bone resection, the opening either from the foraminal side or interlaminar side is relatively narrow. Therefore, the surgeon must be very familiar with bone drilling to perform the endoscopic surgery in this area. Furthermore, it is imperative that there must be zero manipulation of the spinal cord to avoid injuring the spinal any further. In this presentation we demonstrated the extraforaminal approach and interlaminar approach respectively.

Conclusion

Full-endoscopic spinal surgery is another good alternative for soft thoracic disc herniation. It offers excellent visualization of the surgical field. The patient can recover faster due to minimal tissue traumatization. However, it is highly specialized procedure that needs specialized training.

Education and Professional Work

168 • SUKHUMVIT 85 • BANGJAK • PRAKANONG • BANGKOK 10260 • THAI LAND TELEPHONE: +66 2 730 0333 • MOBILE: + 66 81 808 1188 FACSIMILE: +66 2 730 0777 • EMAIL: Verapan@Bumrungrad . com

SPECIAL CLINICAL TRAININGS

2007

International Training Course for Full Endoscopic Spine Surgery Herne/Cologne, Germany

2005

Radiosurgery and Radiotherapy BrainLAB Academy, Germany

2005

Gamma knife training

Karolinska University Hospital Gamma Knife Center, Stockholm, Sweden

SPECIAL CLINICAL INTERESTS

Full endoscopic lumbar and cervical surgery

o affiliated with St Anna Hospital Herne, Germany

o jointly organize annual training course for spine surgeons in Asia

o co-instructor of training course in Germany

o supervises training at Ramathibodi Hospital

Percutaneous pedicular screw with minimally invasive inter-body fusion (supervises training at Ramathibodi Hospital)

Minimally invasive neurosurgery



MISS for Tuberculous spondylitis

Wiwat Wajanavisit

Ramathibodi Hospital, Mahidol University

Tuberculosis occurs in every part of the world. In 2020, the largest number of new TB cases occurred in Asia, with 60% of new cases. TB spine still often occurs and causes devastated results. The standard operation for TB spine is anterior approach to undergo abscess drainage, debridement and fusion with bone graft. MISS is another choice for the patient who is malnourished and could not tolerate to a major surgery. Percutaneous Endoscopic Lumbar Debridement (PELD) under local anaesthesia is able to drain the surrounding abscess and also the epidural abscess. Endoscopic debridement could successfully remove debris, caseous necrosis and sequestrated disc of TB spine.

Education and Professional Work

DATE OF BIRTH 20th June 1956 PLACE OF BIRTH Bangkok, Thailand
20/06/2016 –present Department of Orthopaedics Faculty of Medicine, Ramathibodi Hospital, Mahidol University

OFFICIAL APPOINTMENT 24th September 1990

TEL: +662-201-1589, FAX: +662-201-159 E-mail: [HYPERLINK "mailto:wiwat.waj@mahidol.ac.th"](mailto:wiwat.waj@mahidol.ac.th)
wiwat.waj@mahidol.ac.th



Percutaneous endoscopic transforaminal lumbar interbody fusion: a novel technique- sentinel pinning with lateral retractor for protection of exiting root

Yi-Hung Huang^{1,2}

1. Chia Yi Christian Hospital 2. National Cheng Kung University Hospital Taiwan

The endoscopic spine surgery (ESS) is rapidly developed and ESS combined with TLIF(endo-TLIF) is new trend due to the least traumatization. The safe zone of foramen (Kambin triangle) is so limited, therefore implanting a cage into disc space away from the exiting root or dura injury is a major challenge. We developed a novel technique "sentinel pinning with a retractor" to protect the exiting root as application of tunnel protector and to implant a fixed size cage. The complete procedures were well described, and effectiveness was surveyed.

Methods and material

We inserted contralateral percutaneous pedicle screws firstly, inserted the guide-pin to the SAP, performed foraminoplasty, discectomy and endplate preparing and inserted the sentinel pin docking at inferolateral border of the cranial vertebral body under the monitor of endoscope and fluoroscope. We harvested synthetic bone graft mixing with bone marrow aspirated from vertebral body and implanted a fixed size cage through the safe quadrangular space created by sentinel pin and lateral retractor. We secured the screws and rods finally. Demographics of patients, operation time and blood loss were recorded. Preoperative and postoperative Visual Analogue Scale of back and legs and ODI scores were quantitatively assessed at 1, 3, 6, and 12 months after surgery.

Results

To Dec.2019, a total of 35 patients and 45 levels (mean age 62.2 y/o) were evaluated. The overall mean VAS score for back pain improved statically significantly, and mean ODI scores from 50.9 to 3.6 ($P < 0.01$) postoperatively was significantly improved with a mean follow-up of 15 months There was no postoperative permanent exiting root injury, iatrogenic durotomy and other neurogenic damage.

Conclusions

Postoperative scores for endo-TLIF by this novel technique significantly improved and no disabled complications. The procedure could be considered as a safe and effective TLIF.

Education and Professional Work

Department of Orthopaedic Surgery
Chia Yi Christian Hospital
Assistant professor
E-mail: cychaudiofan@gmail.com

Medical Association member:

1. Taiwan society of endoscopic spine surgery (TSESS): founding president
2. Pacific and Asian Society of Minimally invasive Spine Surgery (PASMIS): board member
3. Faulty member of Society for Minimally Invasive Spine Surgery (SMISS)
4. Taiwan Mini-invasive Spine Surgery Association: board member
5. Taiwan Spine Society
6. Taiwan Surgical Association
7. Formosa Association of the Surgery of Trauma
8. Taiwanese Osteoporosis Association



Endoscopic Lateral Lumbar Interbody Fusion (ELLIF): improved techniques and complication managements

Yoshinori Kyoh

Director of Kyoh Orthopaedics & Neurosurgery Clinic

Abstract

We started to perform Endoscopic Lateral Lumbar Interbody Fusion (ELLIF) five years ago at our clinic. In these five years, the number of operated inter vertebrae segments amounted to about 200. In this series, two serious complications occurred. Fortunately, in both cases, the patients were able to return to society. After the second case, we temporarily suspended the procedure of ELLIF and reviewed the indications and techniques, and worked on the development of a dedicated flat muscle hook that allows the light source to reach into the deep areas, as well as a transparent polyvinyl chloride sheath that can be attached to the endoscope, and we also worked on the renovation of the shape of the sheath to be placed at the end. After the completion of the development, we resumed ELLIF. Currently, we have obtained very trustworthy surgical procedure and have started to perform ELLIF not only in a lateral position but also in a prone position. In this presentation, I will show how to perform ELLIF without complications.

Education and Professional Work

CURRICULUM VITAE

Yoshinori Kyoh

Director of Kyoh Orthopaedics & Neurosurgery Clinic

PROFESSIONAL ADDRESS AND TELEPHONE:

Kyoh Orthopaedics & Neurosurgery Clinic

54-Misono-cho, Amagasaki-city, Hyogo, 660-0861 Japan

TEL+81-6-6411-0714 FAX+81-6-6411-5476

E-mail: yanghoonk@yahoo.co.jp (PC & iPhone)

BOARD CERTIFICATION

The Japanese Orthopaedic Association

The Japanese Society for Spine Surgery and Related Research

AWARD

Best Oral Presentation Award -3rd Place-


The 7th ACMISST & 18th KOMISS, 24-25 May, 2019, Seoul, Korea



Full endoscopic thoracic decompression

Chien-Min Chen

Changhua- Christian Hospital



Full-endoscopic Translaminar Approach for Cranially Migrated Lumbar Disc Herniation

Shigeki Urayama

Mizuno kinen Hospital

Objective: The purpose of this study was to evaluate clinical outcomes of translaminar approach for preforaminal disc herniation cranially migrated in the medial side of pedicle of the lumbar spine using full-endoscopic spine surgery system.

Methods: Thirty patients (23 men and 7 women) participated from January 2012. The affected level was L2/3 in 2, L3/4 in 10, L4/5 in 15, and L5/S1 in 3 patients. All patients but one complained of an exiting nerve root syndrome with motor and sensory deficits. Mean follow-up periods were 30 months (3- 76 months).

Surgical technique: Indigocarmine is injected to stain herniated disc materials before the operation. Under general anesthesia bone hole (10 millimeters in diameter) is accurately made in the lamina overlying the extruded disc fragments. After inner cortical bone of lamina is exposed smoothly, epidural exploration starts at the insertion of the yellow ligament or on the yellow ligament. Bone hole is enlarged with Kerrison forceps. In the epidural fat tissue along the lateral border of thecal sac, dissection is performed to find blue-stained extruded disc fragments. Drainage should be set. The patients are able to walk on the day of surgery.

Results: Mean operative time was 151 minutes (86- 270 minutes). Complication associated with surgery occurred in 4 patients, dural tear, fracture of inferior process, and transient progression of palsy. J OA score was 3-23 points (mean, 11.6 points) before surgery, and improved by 25-29 points (mean, 27.8 points) at the latest observation. VAS score of leg pain was preoperatively 50-100 mm (mean, 75mm), and also improved to 0 mm in all patients but one (30 mm) at the final follow-up period.

Conclusion: This approach is the less-invasive and efficient technique to treat lumbar disc herniation encroaching on the exiting nerve root in the preforaminal zone.

Education and Professional Work

NAME: SHIGEKI URAYAMA (Japan)

OFFICE: Mizuno Memorial Hospital

ADDRESS: 〒123-0841

6-32-10 Nishiarai Adachi Ward Tokyo, Japan

E-MAIL: u9r2a_ya4ma@yahoo.co.jp

1980: MD degree, Hamamatsu University School of Medicine

1986: PhD degree, Toyama Medical and Pharmaceutical University, Graduate School of Medical Sciences

MEMBERSHIP

Japanese Orthopaedic Association

Japanese Society for Spine Surgery and Related Research

Japanese Society of the Minimally Invasive Spine Surgery

Japan Society for the Study of Endoscopic Surgery

BEST PAPER AWARD

The 17th Annual Meeting of the Japan Society for the Study of Surgical Technique for Spine and Spinal Nerves (2010)

Percutaneous Vertebroplasty with Hydroxyapatite under Local Anesthesia for the Treatment of Osteoporotic Vertebral Burst Fractures. J. Spine Res. 2:1230-1235, 2011



Microendoscopic resection of the transverse process for treatment of chronic low back pain with Bertolotti's syndrome.

Kazunari Fushimi
Gifu Prefectural General Medical Center

Abstract:

Bertolotti's syndrome is a rare cause of low back pain among young patients. We present 15-year-old boy who suffered from chronic low back pain. X-ray and CT showed pseudoarticulation between right transverse process of the L5 and sacral alar. Anesthetic injection at pseudoarticulation provided only temporary pain relief. Posterior resection has been performed through microendoscopy. Partial resection of the transverse process was successfully performed. However, after the surgery, he complained insufficient palsy of right L5 nerve root. L5 nerve palsy gradually resolved without any additional surgical procedure, and fully recovered 6 months after the surgery.

Education and Professional Work

Kazunari Fushimi, M.D., Ph.D.

Chief of Orthopaedic Surgery, Department of Orthopaedic Surgery, Spine Surgery Center,
Gifu Prefectural General Medical Center.

4-6-1 Noishiki, Gifu-City, Gifu 500-8717, Japan.

e-mail address: fushimi-kazu@gifu-hp.jp

Professional Background

1995- 1997 Resident in Dept. of Orthopaedic Surgery, Gifu University Hospital.

1997- 2001 Orthopaedic Surgeon, Dept. of Orthopaedic Surgery, Hikone Municipal Hospital (Shiga, Japan).

2001-2005 Spine Surgeon, Gifu University Graduate School of Medicine.

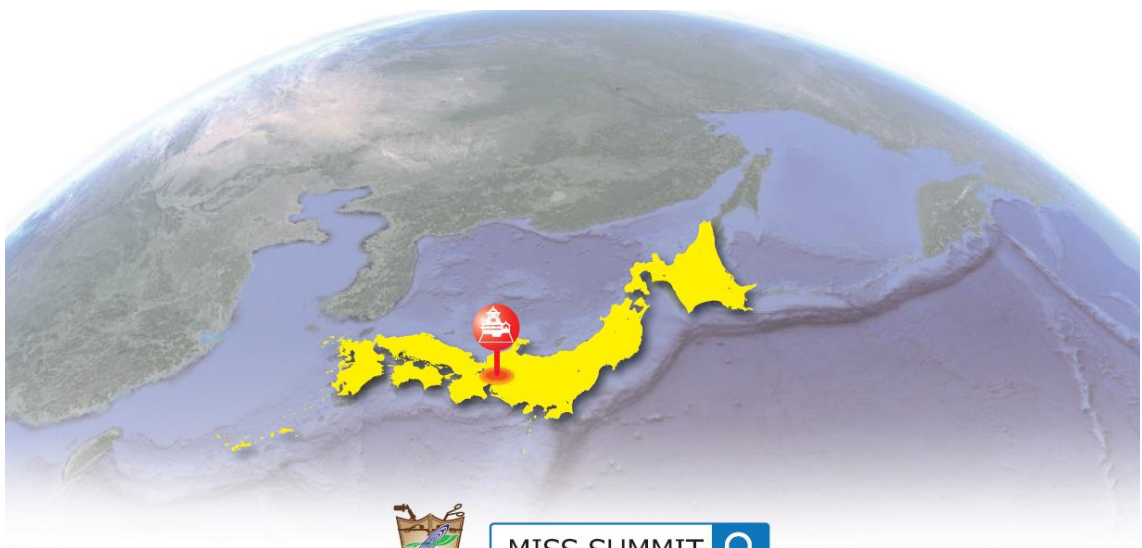2012-2015 Chief of Orthopaedic Surgery, Dept. of Orthopaedic Surgery, Kizawa Memorial Hospital.

2015-2021 Associate Professor, Dept. of Orthopaedic Surgery, Gifu University Graduate School of Medicine.

2021-2022 Chief of Orthopaedic Surgery, Dept. of Orthopaedic Surgery, Spine Surgery Center, Gifu Prefectural General Medical Center.

Program

Lectures



MISS SUMMIT 

<http://missummit.com>



Management of Tuberculous Spondylitis With Minimal Invasive Surgery Debridement: A Case Series

Abdul Kadir Hadar

Department of Orthopaedic & Traumatology, Hasan Sadikin General Hospital – Padjadjaran University

Background

Indonesia is the 2nd most country with high incidence of Tuberculosis with the rate of 391 per 100.000 population. Tuberculous spondylitis accounts for up to 5% of tuberculosis (TB) cases and represents about 50% of all skeletal manifestation of TB. Open debridement is the common procedure for treating tuberculous spondylitis, however it is related with more complications and increasing risk for more morbidities. Minimal invasive surgery with percutaneous transforaminal endoscopy and percutaneous transpedicular surgery gaining more popularity because of its advantages compared to traditional open surgery. In this study, we present 8 cases of tuberculous spondylitis treated with minimal invasive surgery debridement.

Method

8 patients with tuberculous spondylitis were treated with percutaneous transforaminal endoscopic debridement (5) and percutaneous transpedicular debridement (3) surgery. Clinical outcomes were evaluated based on postoperative complications, length of stay, and Visual analogue scale (VAS) during 1st week, 2nd week and 4th week post operatively.

Result

There were no major complications were found in the period of 4 weeks, post-operative anemia (1), wound dehiscence (0) and there was no surgical site infection. Mean length of stay of 8 patients were 2.8 ± 0.7 days, The mean VAS during 1st week was 2.2 ± 0.1 , 1.5 ± 1.2 during the 2nd week, and 0.4 ± 0.6 during the 4th week.

Conclusion

Minimal invasive surgery for tuberculous spondylitis with percutaneous transforaminal endoscopic debridement and percutaneous transpedicular debridement showed a good clinical outcomes on short-term follow up and could be an alternative management for tuberculous spondylitis.

Education and Professional Work

Phone +6222 2035477

Email orthounpad@gmail.com

Residence

Jalan Banyak Cipta Kidul Nomor 10,

Tatar Banyak Sumba, Kota Baru Parahyangan

Padalarang, Jawa Barat, Indonesia

Phone +6281221689217

Email dedeng_haddar@yahoo.com

Degree conferred : Orthopaedic Spine Consultant

Orthopaedic Residency September 2011 - August 2016

Department of Orthopaedics and Traumatology

Hasan Sadikin General Hospital

Faculty of Medicine Universitas Padjadjaran

Bandung, West Java, Indonesia

Degree conferred : Specialist in Orthopaedic Surgery

Compulsory Internship 2004 – 2006

Saiful Anwar General Hospital

Faculty of Medicine Universitas Brawijaya

Malang, East Java, Indonesia

Degree conferred : Dokter (Medical Doctor)

Medical School 2000 – 2004



Strategies for Expanding Your Endoscopic Techniques

Akarawit Asawasaksakul

Back pain Clinic, Ramkhamhaeng Hospital, Bangkok,

Recently, Endoscopic spine procedures are gaining more popularity among spine surgeons around the world. With smaller incision, effective decompression, lessen hospital stayed and the result that have no different from conventional surgery, Endoscopy are now very close becoming a gold standard in treating many spine pathologies. From these reasons, draw interest in many spine surgeons who want to adopt this modality and start the journey on their own. What we all must face is a learning curve that is probably steeper compare to what we familiar with and the results of the procedure itself is usually operator dependent. This means that to effectively climb the curve, we need more strategic planning. From my experiences assisting spine surgeons in Thailand doing their first few cases, I saw some of interesting points that can be beneficial to surgeons who want to start doing endoscopy. In this presentation, I try to focus on how to select your first few cases, that is crucial to maintain your motivation and confidence to do more complexed cases in the future and I would like to use this opportunity to share my thought on this point alongside the process of learning, observation & practicing.

Education and Professional Work

Name & degrees


Akarawit Asawasaksakul MD, Msc (Clinical Science)

Contact Information

- Mobile: +6681-9090254
- Email: Asawasaksakul@hotmail.com

Honors and Awards

- 2017: Scientific Chairman & Organizing Committee, ASEAN Minimally Invasive Spine Surgery & Techniques 2018 (ASEANMISST 2018), Bangkok Thailand
- 2017: Reviewer of Medicine Journal
- 2017: Invited Speaker for China-Thailand Forum of Spine Minimally Invasive, Beijing, China
- 2018: Organizing Committee and Country Representative, ASEAN Minimally Invasive Spine Surgery & Techniques 2019 (ASEANMISST 2019), Manila, Philippines
- 2019: Faculty & Organizing Committee, KOSESS & ASEANMISST Joint Winter Camp 2019, Bangkok, Thailand
- 2020: Speaker, East meets West (Endoscopic Spine Surgery Webinar)
- 500+ cases experience in Endoscopic Spine surgery



Complete resection of sticky ossified dorsal meningioma without neurovascular complications.

Ali Hammed

TISHREEN UNIVERSITY HOSPITAL

Spinal meningioma is a common tumor. It represents 25% of all primary intra spinal tumors. Calcifications in cases of spine meningioma are rare, and gross calcification was only observed in 1% to 5% of all cases of spinal meningioma. Cases of completely ossified spinal meningioma are even rarer. The classification by the World Health Organization (WHO) states that the histological classification of ossified meningioma has been categorized as a phenotype of meningioma with mesenchymal component expression.

We report a case of A 75-year-old female presented with progressive heaviness in the lower limbs with gait disturbance and paresthesia of the lower limbs for approximately 5 weeks. Neurological examination revealed motor power grade of 4 for all muscle groups of the lower limbs and hypoesthesia with a sensory level below T10.

Magnetic resonance imaging (MRI) revealed an intradural extramedullary plate-shaped mass compressing the spinal cord at T7-T9. The mass showed hypointensity on both T1 and T2 images compared to the spinal cord. Computed tomography without enhancement depicted a completely calcified intradural mass.

Although the lesion was very sticky to neurovascular components, Simpson grade I was achieved. Pathologic evaluation revealed psammoma bodies, which suggested calcified meningioma. Neurologic symptoms subsided dramatically and 2 weeks after the surgery, the patient was ambulatory without any disturbance in gait.

The surgical strategy for ossified meningiomas differs from that for other classical cases of meningiomas because central tumor debulking can be challenging. Meticulous microsurgical dissection and using high drill and Kerrison rongeur may help in softening the tumor and can facilitate total tumor removal.

Education and Professional Work

(+963) 993724417 alihaamed9@gmail.com

<https://www.facebook.com/ali.hammed.311> Althawra street, Lattakia, Syria

RESEARCHER AND RESEARCH REVIEWER IN INTERNATIONAL JOURNALS

1. BMC Musculoskeletal Disorders.
2. Interdisciplinary Neurosurgery: Advanced Techniques and Case Management.
3. World neurosurgery.
4. Medicine.
5. Frontiers in Neurology, section Neurotraum.
6. Journal of oncology.
7. Clinical Case Reports.

HONOURS AND AWARDS

Global Neurosurgical Update and Educational Symposium - Best E-Poster – David and Lya Neumann Foundation award



Pathology oriented approach in spine endoscopy

Bhupesh Patel
Asian Superspeciality Hospital

In era of rapidly evolving medical technology it is very pertinent to develop minimally invasive technique in spine surgery that can cause minimal damage to the host tissue and effectively gives same results what open surgery could do

Endoscopic technique is the answer for that

We have different endoscopic approaches for degenerative and traumatic spine pathologies

There is no consensus for single approach for all kinds of pathology

In this presentation I am trying to chennelize particular endoscopic approach for particular pathology of degenerative spine disease

Education and Professional Work

Dr Bhupesh Patel (D.Ortho, DNB Ortho (Mumbai), MNAMS) Fellowship Trained Spine Surgeon (Korea, Japan)
Consultant Minimally Invasive Spine Surgeon and Interventional Pain management specialist

Dr Bhupesh Patel is the pioneer in minimally invasive spine surgery especially spine endoscopy and small incision spine surgery. He believes in philosophy of "A la carte approach" (do what is necessary) by minimising damage to the body.

He always says "SMALL IS BEUTITIFUL AND LESS IS BETTER AS LIKE MINIMALLY INVASIVE SPINE SURGERY"

Dr Bhupesh Patel is Orthopaedic surgeon by profession but devoted his carrier to the Spine surgery and axial pain management.

Dr Bhupesh Patel's dream goal is to provide spine care service by holistic and comprehensive approach. No one should suffer from spine problems without diagnosis and their treatment by combining all the available modality of spine care in the present era.



Clinical outcomes of interlaminar percutaneous endoscopic uniportal pars decompression for lumbar spondylolysis

Chaiyaporn Siramanakul

Department of Orthopaedics, Paolo Phaholyothin Hospital

Objective: To evaluate the clinical and radiological outcomes of a novel full endoscopic procedure performed via an interlaminar approach to decompress entrapped nerve roots in patients with lumbar spondylolysis.

Methods: We reviewed 11 patients who underwent interlaminar percutaneous endoscopic pars decompression. Patients with back pain and dynamic lumbar instability were excluded from the study. Clinical parameters related to outcomes, including the Oswestry Disability Index (ODI) and visual analog scale (VAS) for leg pain, were assessed before and after surgery. The radiological outcomes, vertebral slippage percentage, and motion radiographs were evaluated preoperatively and postoperatively.

Results: Of the 11 patients involved in the study, 5 had spondylolysis alone, of which 1 had spondylolysis at L3-4 and L4-5, and 4 at L5-S1; and 6 patients had spondylolysis in combination with spondylolisthesis, of which 4 had involvement of L5-S1, 1 had involvement of L4-5, and 1 had involvement at L3-4. At a mean follow-up period of 22.64 months, 63.3% of patients achieved more than 50% improvement in ODI scores, and 90.91% of patients achieved more than 50% improvement in the VAS score. Spondylolysis with vertebral slippage had inferior ODI improvement outcomes as compared to spondylolysis alone, but the VAS was not significantly different. No significant difference was observed between the slippage percentage observed between the pre- and post-operative periods. However, 1 patient experienced vertebral slippage after surgery, although fusion surgery was not required.

Conclusions: Interlaminar percutaneous endoscopic pars decompression is a safe and successful treatment for patients with stable lumbar spondylolysis and nerve root compression. Even in situations in which vertebral slippage occurs, spinal fusion may not be the best option for all patients with lumbar spondylolysis.

Education and Professional Work

Chaiyaporn Siramanakul, M.D.

Department of Orthopaedics, Paolo Phaholyothin Hospital, Thailand

Email Address: chaisira@hotmail.com

Academic Appointment:

2019-2020 Secretary General of Computer Assisted Orthopaedic Surgery Thailand Society

2014-2021 Computer Assisted Orthopaedic Surgery Thailand Society Committee

2016 13th Computer Assisted Orthopaedic Surgery Asia Pacific Organizing Committee, Pattaya, Thailand

2018 Scientific Program Chair of 14th Computer Assisted Orthopaedic Surgery Asia Pacific Meeting, Pattaya, Thailand



Application of endoscopic surgery in spine infection

Chang, Chien-Chun
China Medical University Hospital

The optimal indication and timing for surgical management for spine infection remains unclear, seemingly because of a lack of research on the subject. Traditionally, surgery is indicated for a neurological deficit, structural deformity, or nonsurgical treatment failure (Quinones et al., 2004; Rodts, 2004; Stoffel et al., 2011b; Pola et al., 2012). The main goals of surgical treatment are the maximal preservation of neurological function, the maintenance of structural alignment, and the elimination of the infection (Schinkel et al., 2003; Mann et al., 2004). However, surgical interventions are associated with considerable number of comorbidities (Deininger et al., 2009). Therefore, in recent years, minimally invasive surgery has been reported as an effective and efficient treatment option, especially for elderly or immunocompromised patients or those with multiple comorbidities. In this speech, we review all the infection spine cases in our hospital. We retrospectively compare the clinical result of open surgery and endoscopic surgery between the patients. We try to make a consensus and guideline for spine infection treatment with endoscopic surgery.

Education and Professional Work

Current Employments:

1. Attending doctor, Department of Orthopaedic Surgery, China Medical University Hospital, Taichung, Taiwan
2. Chief, minimally invasive spine surgery and endoscopic surgery, Spine center, China medical university hospital, Taichung, Taiwan

Interests:

1. General Spine Surgery: deformity, degenerative disease, trauma, tumor
2. Minimally invasive spine surgery: Percutaneous Endoscopic surgery, MIS TLIF
3. Navigation spine surgery
4. Minimal incision joint replacement (Knee and hip arthroplasty)

Board Certification : Board of Orthopaedics, R.O.C.

Membership:

1. Director, 8th, 9th, 10th Taiwan Society of Minimally Invasive Spine Surgery (TSMISS)
2. General Secretary, 7th Taiwan Society of Minimally Invasive Spine Surgery
3. Member, Formosa Medical Association, Taiwan
4. Member, Taiwan Orthopaedic association, Taiwan
5. Member, American Academy of Orthopaedic Surgeons
6. Member, Joint Reconstruction Society, Republic of China



Uni-portal Percutaneous lumbar stenotic decompression (PSLD) for Treating Degenerative Lumbar stenosis. A case series with minimal two years follow-up.

Ching-Hsiao Yu

Department of Orthopaedic Surgery, Taoyuan General Hospital

【Background】

Full-endoscopic spine surgery (FESS) has gained popularity because it is the least minimally invasive technique compared to traditional open and tubular surgeries currently. Objective of this study is to evaluate the clinical outcome of uni-portal percutaneous stenotic lumbar decompression (PSLD) in the treatment of degenerative lumbar stenosis with at least two-years follow-up.

【Methods】

From March, 2018 to Dec, 2020, we collected 152 consecutive patients including 130 degenerative lumbar stenosis and 22 stable stenotic spondylolistheses. All patients sustained intermittent claudication and leg pain with or without mild back pain. One-portal percutaneous stenotic lumbar decompression (PSLD) with unilateral laminotomy bilateral decompression surgery (ULBD) was performed for all patients. The presenting symptoms, operation method, operation time, length of hospital stays, and complications were reviewed. Functional score as back and leg pain according to the visual analog scale and Oswestry Disability Index scores were assessed. Minimum follow-up was 24 months.

【Results】 Sixty-six male and 84 female patients, with average aged 62.6 years (32-84 years) were reviewed. Preoperative intermittent claudication were presented in all 152 patients whereas 80 patients sustained remarkable leg pain. Unilateral laminotomy bilateral decompression surgery (ULBD) was performed for all 152 patients and 190 segments. One level decompression was 114 patients while 38 patients has two-level operations simultaneously. The mean operation time was 75 minutes (55- 160 minutes) for each level. The average length of stay was 3.2 days. No patients used morphine for pain control. Six patients sustained intraoperative durotomy. There was no postoperative infection. Ten patients sustained post-operative neuritis and all of them recovered well later. At the latest follow-up, 8 patient received revision surgery. Five of them underwent fusion surgery where 3 patients received revision endoscopic decompression surgery. The mean ODI was significant improved from 52.2 ± 2.1 to 17.2 ± 2.6 . Modified Macnab criteria were excellent in 60 patients (39.5%), good in 62 (40.7%), fair in 21 (13.8%), poor in 9 (5.9%).

【Conclusion】

In carefully-selected patients, percutaneous stenotic lumbar decompression (PSLD) is a safe and effective minimally invasive surgery for patients with lumbar stenosis.

Education and Professional Work

Dr. Ching-Hsiao Yu, MD

AFFILIATION

Spine Chief, Department of Orthopaedic Surgery, Taoyuan General Hospital, Taiwan

MEMBERSHIP

Secretary General, Taiwan Society of Endoscopic Spine Surgery (TSESS)

Supervisor, Taiwan Society of Minimally Invasive Spine Surgery (TSMISS)

Taiwan Orthopaedic Association (TOA)

Taiwan Spine Society (TSS)

Taiwan Osteoporosis Association (TOA)

Asia Pacific Orthopaedic Association (APOA)

E-mail: smalloil1205@yahoo.com.tw



Surgical strategy in selection of ideal endoscopic approach in various degenerative lumbar pathologies

Chul-Woo Lee
St. Peter's Hospital

Endoscopic spinal surgery (ESS) emerged and was developed as an alternative to previous traditional methods for degenerative lumbar disease. With such radical development of ESS, endoscopic surgeons have extended the surgical indication of ESS from disc herniation to lumbar canal, lateral recess, and foraminal stenosis. Several authors reported clinical success of endoscopic spinal surgery for various lumbar pathologies by using several kinds of endoscopic approaches. Nonetheless, articles that mention and deal with about technical description in detail, limitations, and pitfalls of each endoscopic approach with comparison are scarce.

Four different endoscopic Approaches (transforaminal, midline, contralateral, paraspinous) have their own unique surgical characteristics including advantages, disadvantages, and therapeutic boundary. Appropriate approach selection and established surgical technique are prerequisite for the successful result of ESS in various cases of lumbar degenerative diseases

The purpose of this presentation is to introduce the technical methods of the four different endoscopic approaches for lumbar pathologies in detail and review their efficacy and clinical feasibility. The presenter also will discuss the optimized application of endoscopic approach technique for the treatment of individualized degenerative lumbar pathologies by comparing four different endoscopic approaches

Education and Professional Work

CHUL-WOO LEE, M.D., PhD.

St. Peter's Hospital
Dogok-Dong 914-2, Kangnam-Gu, Seoul, Korea
Phone: +82-2-554-3472; Fax: +82-2-574-9414
Website : www.goodspine.or.kr

CURRENT POSITION

Staff surgeon, Neurosurgery Dept., St. Peter's hospital
Clinical Professor, Soonchunhyang university medical school
A member of insurance committee of Korean Spinal Neurosurgery Society
A executive director of the Korean Minimally Invasive Spine Surgery Society (KOMISS)
A planning and coordination director of the Korean Research Society of the Endoscopic Spine Society (KOSESS)



Extended indication and technique of Uniportal endoscopic decompression in degenerative lumbar spine

Gun Keorochana

Ramathibodi Hospital, Mahidol University

The decompressive surgery for degenerative lumbar spine includes discectomy, laminectomy, laminotomy, intradiscal therapy, facet cyst removal and facet joint denervation. Uniportal endoscopic surgery can be used in almost all of these problems. Main approaches of uniportal endoscopic spine are posterolateral (includes transforaminal and paraspinal) and interlaminar technique. The docking point, orientation, 3D anatomy, scope view and surgical skill are difference between these 2 approaches. Different types and locations of the pathology, also instrument availability and surgeon experience are the important factors of approach selection.

Transforaminal approach is conventionally used for long time through Kambin's triangle and can address most of the paracentral to foraminal lesion area. Paraspinal approach was established in cases of narrowing disc space or Kambin's triangle and upper foraminal area lesions, and can address more at foraminal and extraforaminal area. Interlaminar approach can reach to central, paracentral pathologies, also both unilateral and contralateral recess area, and can be extended up and down to area medial to pedicles. Moreover, endoscope in interlaminar approach can be tilted to contralateral foraminal lesion. This method can decompress ipsilateral and contralateral traversing roots and contralateral exiting root of upper level (called three roots decompression) Furthermore, uniportal endoscope can be applied in medial branch denervation for facet joint arthritis (rhizostomy) which can increase visualization and accuracy of this abrasive procedure.

With the innovated equipment, instrument and tool and the improvement of surgical technique and surgeons' skill, the indication for use of uniportal endoscopic spine surgery has been extended to all kinds of decompressive lumbar procedures including severe and multiple level stenosis, selected difficult cases e.g. severe scoliosis, inadequate bone stock, or facet joint denervation. Endoscopic spine surgery should be more developed and evolved continuously in the future.

Education and Professional Work

NAME: Gun Keorochana M.D.

POSITION: Associate Professor

SEX: Male

PLACE OF BIRTH: Bangkok, Thailand

PRESENT ADDRESS: Spine Unit, Department of Orthopaedics,

Ramathibodi Hospital, Mahidol University

Rama VI Rd., Rajthevee, Bangkok,

Thailand 10400

TEL. +66 2 2011589 FAX. +66 2 2011599

e-mail: gun_keo@yahoo.com gun_keo@hotmail.com

AWARDS, HONORS

APOA Spine Traveling Fellowship 2005 to Hong Kong, Sendai and Taipei

AREA OF INTERESTS

Spinal interventions

Endoscopic spine surgery

Minimally invasive spine surgery

Vertebroplasty/Kyphoplasty

MIS TLIF

XLIF

MIDLF

Percutaneous pedicle screw



The Biportal endoscopic Posterior cervical inclinatory foraminotomy

Kwan-Su (David) Song
Department of Neurosurgery of Him-Plus Hospital

Posterior cervical foraminotomy (PCF) is a minimally invasive surgical technique whose superior surgical value is once again being highlighted with the development of spinal endoscopes.

Nevertheless, sometimes when surgeons operate PCF surgery, they must decide between facet violations and incomplete decompression.

Even if more than 50% of the facet violation, it would be better to perform the surgery with more emphasis on the decompression because of the regeneration effect. But the stress on the surgeon until the initial recovery after surgery will be considerable.

Posterior cervical inclinatory foraminotomy (PCIF) has some advantages of facet preservation through facet undercutting, trajectory along the root, and making it easier to perform instruments and tasks.

This presentation introduces surgical techniques and tips for each step.

Education and Professional Work

Name: Kwan-su Song, M.D.

Date of Birth: November 8, 1975

Place of Birth: Korea, Republic of

Address:

Department of Neurosurgery, Him-plus hospital,
13, Sinwolkeun-gil, Suncheon-si, Jeollanam-do, Republic of Korea

Tel: +82-61-804-5000/ Mobile +82-10-7120-0955 Fax: +82-61-804-5119

E-mail: sabiston002@hanmail.net, sabiston001@naver.com

Advantage

- An award from the Minister of Health and Welfare. (2008)
- Experience of about 2000 cases of operation of spinal surgery
- The annular announcement of NAVI symposium of Endoscopic Spine Surgery (2018.07.15)
- A best award case presentation from KOSESS (2018.09.30)
- The annular announcement of The 7th ACMISST & 18th KOMISS international symposium (2019.03.24-25)
- The annular announcement of The 19th KOMISS (2020.12.05)



Lumbar Nerve Root Fibrous Entrapment Treated By Full Endoscopic Interlaminar Approach

Marcio Robertti Ramalho Da Cunha
NEUROSURGEON OF THE GENERAL HOSPITAL

INTRODUCTION

We have a lot of causes to entrap the lumbar nerve root s, bringing sciatica as a major symptoms, these entrapments can be caused by many etiologies, such as : Intervertebral disc herniation,spinal stenosis, formation of osteophytes and adhesive fibrous entrapment . Even though the MRI did not demonstrate any signal of radicular conflict, the patients below had a typical sciatica related to their level as a target point of pain.

METHODS

A 58-year old woman came to our clinic in march 2017, she had no previous historical background of any surgical spinal procedure, complaining of severe right sciatica aggravated by walking and coughing. She also had numbness and tingling sensation in the lateral posterior part of her right foot,s . On physical examination the straight leg raise test was positive at 45degreeeb in association with abolished Achilles tendon reflex. The MRI showed no signals of nerve conflict in the level L5/S1. So, after no response in the conservative treatment for six months, we ´ve decided to make a nerve blockage with a local anesthetic with positive relief for 12 hours. The second one was a male 76 years-old with the same symptoms for more than 06 months with a positive relief after the blockage in the level L5/S1, promoting relief of his symptoms for 08 hours.

RESULTS

We ´ve made both surgical procedures under the basic steps of the Interlaminar full endoscopy . After opening the yellow ligament we could see a total S1 entrapment by fibrous adhesive tissue around the nerve root. After some surgical maneuvers with dissectors and punch scissors, we could liberate the nerve root and get back the free pulsation of the root . The procedure was done under a skin incision of 08 mm and took around 34 minu.The patients had a hospital discharge in less than twelve hours .

CONCLUSIONS

We bring this new concept to treat lumbar nerve root entrapment by the basic steps of the Interlaminar approach, decreasing the chances to entrap again the same level by the fibroses attached to the open procedures .

Education and Professional Work

GENERAL INFORMATION:

NAME: MÁRCIO ROBERTTI RAMALHO DA CUNHA
E-MAIL: maramalho65@gmail.com
MOBILE: 5584994078437
PASSPORT NUMBER: FV-220467
ADDRESS: RUA JAGUARARI 5100 CASA 59 CANDELÁRIA NATAL-RN / BRAZIL

MEMBERSHIP AFFILIATION

- 1) TITULAR MEMBER OF BRAZILIAN NEUROSURGERY SOCIETY (1994)
- 2) TITULAR MEMBER OF BRAZILIAN SPINE SOCIETY (2009)
- 3) A_o SPINE MEMBER
- 3) MEMBER OF LATINO AMERICAN STUDY GROUP OF NEUROENDOSCOPY / GLEN
- 4)CO FOUNDER MEMBER OF BRAZILIAN BRANCH OF I.S.E.S.(INTERNATIONAL SOC. ENDOSCOPY OF SPINAL SURGERY)

PROFESSIONAL QUALIFICATIONS :

PROFESSIONAL QUALIFICATIONS:

- 1) CHAIRMAN OF NEUROSURGERY OF THE GENERAL HOSPITAL NATAL-RN / H.W.G (2014)
- 2) SENIOR STAFF OF THE SPINAL SURGERY AREA OF CLINIC TRAUMA CENTER /NATAL-RN (2007)
- 3) U.F.R.N, ASSISTANT PROFESSOR OF THE NEUROSURGERY DEPARTMENT (1996-1999)
- 4) NEUROSURGEON OF THE GENERAL HOSPITAL NATAL-RN / H.WG (1994- 2018)



Percutaneous Stenoscopic Cervical Decompression/Discectomy in my practice

Matee Phakawech
S-spine and nerve hospital

Introduction: Cervical spine surgical techniques had undergone significant advancement over time. Available treatment options include decompression, open fusion surgery, and disc replacement. Nowadays the development of endoscopic spine surgical instrument gives us the possibility to perform cervical spine surgery in a less invasive manner.

Surgical technique: In my practice 95 percent of cervical spine problem can be fixed with endoscopic surgery. However, traditional open surgery such as laminoplasty and disc replacement is still mandatory in cases with severe nerve compression that have myelopathic symptoms. Nowadays I do endoscopic foraminotomy for patient with nerve root compression, identifying the pain generator based on the dermatome of pain, correlated with x-ray and MRI. The aim of surgery to decompress the nerve root which is causing pain. This surgical technique can be done even in multiple nerve root compression in the same surgical session. Moreover, in some case with acute sequestered cervical disc herniation, the piece of sequestered disc material also can be removed safely under posterior cervical endoscopic surgery. One more benefit of posterior cervical surgery is the surgery can be done even in lower level of cervical spine such as C7-T1, which is difficult approach from anterior, in the same way as upper level.

Conclusion: Endoscopic surgery in cervical spine can be the future of spine surgery. The benefit is less surgical trauma, shorter operative time, and shorter recovery time. However, the surgical technique still evolving and require a steep learning curve.

Education and Professional Work

HOME ADDRESS 150/7 Ladprao 81, Puttaraksa village, klongchaokhunsing, Whangthonglang, Bangkok, 10310
 MOBILE PHONE +66 841957932
 OFFICE ADDRESS S spine and nerve hospital
 532/1 Praditmanutham Rd, Wangthonglang
 Bangkok, 10310
 OFFICE PHONE +66 20340808
 OFFICE FAX +66 20340847
 MEMBERSHIPS IN PROFESSIONAL SOCIETIES
 Medical Council of Thailand
 Royal College of Orthopaedic Surgeons of Thailand (RCOST)
 Spine Surgery Thailand
 Minimal Invasive Spine Surgery Thailand



Revision rates and surgical outcomes in full endoscopic lumbar discectomy

Meng-Huang Wu

Spine Division, Department of Orthopedics, Taipei Medical University

【Introduction】

Lumbar disc herniation (LDH) is a common degenerative spinal disease. Although conventional open discectomy (OD) is the standard surgical treatment, it is correlated with adverse outcomes, including recurrent LDH (rLDH). Minimally invasive surgeries (MISs) for rLDH were developed, such as full endoscopic lumbar discectomy (FELD). The effects of FELD and other such surgical procedures remain under debate.

【Materials and Methods】

A narrative review was conducted to identify studies analyzing causes of and risk factors for rLDH after FELD, the current prevention and treatment strategies and compared the postoperative outcome and complication risk of FELD with those of microendoscopic discectomy (MED) and minimally invasive transforaminal interbody fusion (MIS-TLIF) in rLDH treatment. A search was conducted on PubMed. Both retrospective and prospective comparative studies were included.

【Results】

FELD demonstrates shorter operation time, lower blood loss, and complication rates than OD and MIS-TLIF, but without any significant differences in hospital stay duration and recurrence rate. Besides, FELD were associated with less pain than was MIS-TLIF. FELD has many advantages over the conventional MED including no need for general anesthesia, less or no iatrogenic neurologic damage, low infection risk, direct approach to the extruded disc fragment, minimal disturbance of the intracanal capsular structures, and no interference of scar tissue to reach protruded or extruded rLDH.

【Discussion】

Postoperative magnetic resonance imaging is essential in this surgery. Complete understanding of the surgical anatomy and the fundamental techniques of OD and MIS are the cornerstones for mastering FELD procedures. Recognizing complications of FELD such as nerve root injury, retroperitoneal cavity injury, and great vessel injury are also crucial. Appropriate postoperative monitoring and care massively influence patient prognosis as well.

【Conclusions】

Revision rate for FELD is 5-8%. Revisional surgery via FELD is the most appropriate choice for rLDH because it is associated with highest patient satisfaction in the early stages after surgery but also has higher recurrence rate. MIS-TLIF should be considered for instability and high recurrence risk patients.

Education and Professional Work

Academic Positions :

Associate editor, Clinical diagnostics and imaging, BMC Musculoskeletal Disorders (2018 IF: 2.002)

Academic editor, BioMed Research International (2018 IF: 2.197)

Visiting staff, TMU Research Center of Biomedical Devices Prototyping Production

AOPEER teacher, AO Clinical Investigation and Documentation (AOCID) and the AO Education Institute (AOEI)

Employment Record :

* Director, Spine Division, Department of Orthopedics, Taipei Medical University Hospital (Aug, 2020 - Present)

* Chief Executive Officer, Taipei Medical University Biodesign Center (2021/10/1 - Present)

* Director, Prospective Innovation Center, Taipei Medical University Hospital (Feb, 2022 - Present)

* Vice Director, Prospective Innovation Center, Taipei Medical University Hospital (Jan, 2021 - Feb, 2022)

* Attending Physician, Department of Orthopedic Surgery, Taipei Medical University Hospital, Taipei, Taiwan (July 1, 2015- Present)

* Attending Physician, Department of Orthopedics Surgery, Spine Surgery Section, Chang-Gung Memorial Hospital, Chiayi, Taiwan (Dec. 1, 2011 –June 30, 2015)

* Attending Physician, Postal Hospital, Taipei, Taiwan (Jan. 1, 2016-Present)

* Committee member, Joint Institutional Review Board, Taipei Medical University (2020/1/1~)



Extraforaminal disc herniation: a comparison of surgical technique between full endoscopic discectomy and unilateral bi-portal endoscopic discectomy (UBE)

Nantawat Uttamo
Veterans General Hospital

Extraforaminal lumbar disc herniations are quite rare. Their anatomical structures and the surgical approach are more complexed than intracanalicular disc herniation due to an increased risk of postoperative complications. Nowadays, endoscopic spinal surgery has more roles in the treatment of lumbar disc herniation. Both full endoscopic discectomy and UBE discectomy have been progressively developed to better solve extraforaminal problems and decrease complications. However, techniques and limitations between the 2 approaches are different. Understanding both of them leads to better decision and patient outcome.

Education and Professional Work

Nantawat Uttamo, M.D.

PERSONEL INFORMATION

Name Nantawat Uttamo

Work Address Department of Orthopaedic Surgery, Veterans General Hospital, Bangkok, Thailand

Telephone 087-188-9192

Home Address 291/28 BLOCS 77 Bldg., 6th Fl., Rd. Sukhumvit 77, Phrakonong Nuea, Wattana, Bangkok, Thailand 101100

Telephone 087-188-9192 E-mail Address Nantawat_U02@hotmail.com

PROFESSIONAL MEMBERSHIPS AND SOCIETIES

2010 - present Thai Medical Council

2012 - present AO Trauma membership

2015 - present Royal College of Orthopaedic Surgeons of Thailand (RCOST)

2016 - present Spine Society of Thailand (SST)

2016 - present Thai Society of Minimally Invasive Spinal Surgery and Techniques (ThaiSMISST)

2017 - present ASEAN Minimally Invasive Spinal Surgery and Techniques (ASEANMISST)

2017 - present North American Spine Society (NASS)

2020 - present AO Spine membership

INSTITUTIONAL/DEPARTMENTAL ADMINISTRATIVE RESPONSIBILITIES, COMMITTEE

MEMBERSHIPS, AND OTHER ACTIVITIES

- Interesting case: Spinal infection, Spine News, Issue 5 January 2015
- ThaiSMISST and ASEANMISST committee
- General Secretary, Cadaveric Workshop Co-chairman and Speaker in 4th ASEANMISST in Collaboration with NASS and Cadaveric Workshop 2018, Chiang Mai, Thailand
- International medical coordinator for the Medical Sub-Committee of the Project "lumbar disc surgery for monks, priests of various religions and underprivileged patients", The 50th Anniversary Maha Vajiralongkorn Hospital Foundation
- Reviewer of World Neurosurgery journal



Anatomic Considerations Transforaminal Approach: Clinical implications

Pradyumna Pai Raiturkar

Consultant Spine Surgeon, Deenanath Mangeshkar Hospital, Pune India

Transforaminal access for treatment of Lumbar disc herniations and related pathologies has gained a lot of attention in the 21st century and is regarded as one of the most successful minimally invasive interventions in selected cases. For the traditionally trained spine surgeon the transforaminal access is new and needs more understanding. Transforaminal access is through the Kambin's triangle described by Prof Parvez Kambin. Anatomy and the variations of anatomy especially of the exiting nerve root in the neural foramen is the key to successful planning and execution of transforaminal lumbar surgery without complications. I would describe the historical aspects and review articles describing Kambin triangle anatomy and would also describe way for MRI analysis of the exiting nerve root relation to superior facet. This also helps us in understanding the cannula dimension used for endoscopes and also the fact that time required for endoscopic procedure is also an important consideration while undertaking the same to avoid complications and injury to exiting nerve root.

Education and Professional Work

About me.

I am a practicing orthopedic spine surgeon with an experience of 16 years trained in endoscopic spine surgery at Wooridul Spine Hospital, South Korea with Prof Gun Choi, at Squaw Peak Centre Arizona with Prof Anthony Yeung and also with Prof Ruetten in Germany and Prof Cheol Wong Park in South Korea. Interest in transforaminal, interlaminar and Biportal endoscopic lumbar and cervical surgeries other than deformity, spinal infections Tumours and microscopic interventions.



Full endoscopic rhizotomy in Sacroiliac joint pain : Evidence Based Guideline and Technical note

Saran Pairuchvej
Queen Savang Vadhana Memmorial Hospital

Sacroiliac joint (SI) pain is the condition That can be found among population wide range of age with incidence of 30-60% . The cause of this condition could be from degenerative, inflammatory disease, trauma or Joint disorder. According to the latest guideline,which focused on medication , physical therapy and pain intervention. Radiofrequency ablation of SI joint was one of the treatment option with evidence supported of moderate to long-term outcome improvement. This presentation was about how to assess and manage patients who had SI joint problems. The technical note and preliminary report of patient who undergone endoscopic rhizotomy of SI joint were also demonstrated.

Education and Professional Work

Saran Pairuchvej , M.D.

Chief of Spine unit ,Spine Consultant of Orthopaedics Department

Queen Savang Vadhana Memmorial Hospital ,Sriracha Chonburi , Thailand

Tel: +6638-320-200 ext.1171 , +6681-345-6455

Born: November 12,1981

office address : Queen Savang Vadhana Memmorial Hospital , 290 Jermchompol Rd. ,Sriracha , Chonburi 20110

Email: runsan56@hotmail.com

Certifications

- 2010 Diplomat Thai board of Orthopaedics surgery
- 2010 Hand and Microsurgery workshop, Chiangmai, Thailand
- 2010 AO Advanced course on principles of operative fracture treatment Bangkok,Thailand
- 2011 Visiting fellowship for Spine training, Nishitaga hospital, Sendai, Japan
- 2011 Visiting fellowship for Spine training, Tohoku Chuo hospital, Yamagata, Japan
- 2012 Fellowship of spine surgery, Ramathibodi hospital, Mahidol University,Thailand
- 2013 MIS and microendoscopic spine surgery, Wakayama, Japan
- 2013 Spinal injury center, Fukuoka, Japan
- 2015 Visiting doctors in Hospital de Gap, Gap, France



Posterior lumbar interbody fusion by biportal technique using 30 degrees arthroscope in lumbar degenerative disease

Seok-Bong Jun
Orthopaedisc, Jinju Bon Hospital, Jinju-si, Gyeongsangnam-do

Background

The endoscopic biportal surgical technique have a lot of advantages and Many spine surgeries are being done by this methods

Objectives (or Aim)

The aim of study is to report the technique and advantages of posterior lumbar interbody fusion by bi(two)portal technique using 30 degrees arthroscope in lumbar spondylolisthesis

This study is preliminary clinical results

Methods

Of 70 patients who underwent biportal endoscopic lumbar interbody fusion, 12 patients with multi-level fusion were enrolled in this study. One portal was for irrigation and viewing, the other portal was for working and outflow of water. We used 30 degrees arthroscope to get wider view.

The ipsilateral lamina and facet were removed using burr, punch and narrow osteotome, Percutaneous pedicle screws with cage were used. The patients walked in the first post-op day. Clinical outcome was analyzed by using numeric rating scale (NRS), Macnab criteria serially assessed before the procedure, and at 3 months post procedure. Operation time and postop. Hb were assessed

Results

The NRS about low back pain fell from 7 to 2 scores at 3 months and about leg pain fell from 8 to 1 scores.

According to the Macnab criteria, 'Excellent' was obtained for eight patients, 'Good' results for three, and 'Fair' results for one patient.

For two segments, the average decrease in Hb was 2.1 in the first post-op day, For three segments was 2.8

There was no need for transfusion. Operation time took 2 hours 5 mins in two segments, and 2 hours 50 mins in three segments. There were no significant complications

Conclusions

The short term results show that posterior lumbar interbody fusion by bi(two)portal technique using 30 degrees arthroscope can be an efficient and get early recovery. And This operation didn't require transfusion. and was less invasive But long term results should be researched

Education and Professional Work

Seok-Bong Jung

Orthopaedisc

Spine center, Jinju Bon Hospital, south Korea

AO spine delegate in Korea (2021- 2024)

PASMISS committee in 2020

Member of MISS association in Korea



Transala approach of unilateral biportal endoscopic discectomy for extraforaminal herniated disc L5-S1: technical report and clinical outcome

Songwut Sirivitmaitree

Department Of Orthopedics, Bandung Crown Prince Hospital

Propose: to describe the surgical technique of unilateral biportal endoscopic discectomy for extraforaminal herniated disc at level of L5-S1 and analyze clinical and radiological outcome.

Methods: The retrospective study enrolled 9 patients with extraforaminal herniated disc at level of L5-S1 who underwent transala approach by unilateral biportal endoscopic. We excluded patients with previous surgery and dynamic lumbar instability from this study. The surgical techniques were described step-by-step. The clinical outcomes were assessed as mean the visual analogue scale (VAS) for leg and back pain, Oswestry Disability Index (ODI) at pre-operative and 2 weeks post-operative. The radiographic outcome were assessed segmental instability at pre-operative and 6-month post-operative

Results: a total of 9 cases with 3 males and 6 females were included in the study. The pre-operative mean VAS scores for leg pain significantly decreased from 7.6 to 2.1 ($p < 0.05$)

There was no significant difference in VAS scores for back pain (2.8 pre-operatively vs. 1.8 post-operatively)

The mean preoperative ODI score was 64.8. The postoperative ODI scores were 14.6 ($p < 0.05$). There was no iatrogenic segmental instability. Two patients had paraesthesia and symptoms were resolving for 6 weeks.

Conclusions: transala approach is an effectively to achieve discectomy extraforaminal herniated disc at the L5-S1 level especially minimize violence facet joint and more safely target point of camera and instrument. we expected transala approach is an alternative approach to treat extraforaminal herniated disc at L5-s1 level.

Education and Professional Work

Songwut Sirivitmaitree, MD.

Department Of Orthopedics, Bandung Crown Prince Hospital, Thailand

Email Address: Dr-benz@hotmail.com

Education:

2005-2007 High School: Bodindecha (Sing Singhaseni) School2, Bangkok

2007-2012 M.D.: Faculty of medicine, Khon Kaen University, Khon Kaen, Thailand

Post-doctoral Training

2012-2014 Internship: Udon Hospital, Udon, Thailand

2014-2017 Residency Training In Orthopedics: Phramongkutklao Hospital and College of Medicine, Bangkok, Thailand

2018-2019 Fellowship Training In Metabolic Bone disorder & Ortho Geriatric at Phramongkutklao Hospital and College of Medicine, Bangkok, Thailand

Textbook

Textbook of endoscopic spinal surgery Thailand: Chapter Unilateral Biportal Endoscopic Paraspinal Approach for foraminal and extraforaminal Lesion

Honor, Award

First runner-up Poster award: Risk Factors for Cut out Failure of Proximal Femoral Nail Antirotation in Treatment of Unstable Intertrochanteric Fractures: a Case Control Study. Proceeding of the joint Meeting Of Royal College of Orthopedics of Thailand

Special clinical interest

Endoscopic spinal surgery, an experience over 200 patients



Endoscopic spine surgery in spondylodiscitis

Urawit Piyapromdee

Maharat Nakhon Ratchasima Hospital

Abstract:

In developing nations, spondylodiscitis is a frequent spine issue. Surgical drainage and radical debridement are gold-standard treatments, but they require soft tissue dissection and bone resection during the surgery.

Endoscopic spine surgery is an alternative therapeutic option for spine disease that is minimally invasive to surrounding soft tissue. Spondylodiscitis can also be treated by endoscopic spine surgery.

Endoscopic spine surgery is effective for patients with uncomplicated spondylodiscitis who do not have segmental instability or considerable bone loss. However, it is an alternative for high-risk patients who are unable to withstand open surgery. Endoscopic surgery is performed with only local anesthetic and sedation. The transforaminal technique through Kambin's triangle is the safest method for doing a tissue biopsy that minimizes bone resection and soft tissue damage. The contaminated tissue was effectively removed with the assistance of an endoscope and a fluoroscope. Through the irrigation channel at the endoscope port, continuous saline irrigation will diminish infective content.

An example of spondylodiscitis that did not respond to conservative therapy. The 77 years old female presents with persistent low back pain that does not respond to intravenous antibiotics. A transforaminal endoscopic technique was used to get a tissue sample and remove the infected tissue with saline irrigation. Examination of the tissue revealed a non-tuberculous mycobacterial infection that responded to endoscopic excision and continuing antibiotic treatment.

The advancements in endoscopic spine surgery have altered the treatment approach for spondylodiscitis in recent years. Patients can benefit from accurate tissue diagnosis along with tissue debridement and irrigation while reducing soft tissue damage, resulting in a shorter recovery period for patients, especially those at higher risk for complications.

Education and Professional Work

CURRICULUM VITAE

Name: Mr. Urawit Piyapromdee

Date of birth: 28th January 1982

Place of birth: Nakhon Ratchasima, Thailand

Religion: Christian

Tel. 0816699446

E-mail : Urawit@gmail.com, Urawit.kr@cpird.in.th



Unilateral biportal endoscopic surgery for treating far lateral lumbar disc herniation: technical report and preliminary clinical results

Zhang Wei

Spinal minimally invasive center, Hangzhou Traditional Chinese Medicine Hospital

Purpose To describe a surgical technique for far lateral lumbar disc herniation (FLLDH) using a percutaneous unilateral biportal endoscopic discectomy (UBED) and to analyze early clinical results after endoscopic decompression.

Method Consecutive 11 patients underwent UBED for their FLLDH. Postoperative radiologic images (x-rays, computed tomography [CT], and magnetic resonance imaging [MRI]) were evaluated for neural status and stability. A visual analogue scale (VAS) for the leg pain and the Oswestry Disability Index (ODI) were used to evaluate clinical results in the preoperative and postoperative periods.

Results The mean follow-up periods were 4.1 ± 2.3 months. The mean operative time was 64.7 ± 22.6 minutes. Postoperative MRI and CT revealed complete removal of herniated discs and ideal neural decompression of the treated segments in all patients. Disc height and stability were preserved on postoperative x-rays. Preoperative VAS and ODI scores improved significantly after the surgery.

Conclusion UBED was an effective method for the FLLDH, which provides successful surgical decompression without disturbance of spinal canal. This approach can also allow more easy surgical manipulation and minimize iatrogenic damages of the posterior lumbar musculo-ligamentous structures.

Education and Professional Work

Mobile: 13696369519

Email: volcano8060@163.com

Education

1999-2004, Bachelor, North China Coal Medical College

2007-2010, Master's degree, Weifang medical college

2013-2017, Doctor's degree, Shandong University

Internship and residency

2002-2003, Kailuan Hospital (internship)

2005-2010, Shouguang People's Hospital (residency)

since 2021, Hangzhou Traditional Chinese Medicine Hospital

License

Orthopedic Surgery

Membership

Shandong pain medicine society

Weifang orthopaedics society

Weifang sport medical society

Hobby

Medical illustration

Main Career

Since 2014, minimal invasive spine surgery (UBE/PELD/MED/PVP/PKP/MIS-TLIF under quadrant)



VBE-TLIF

Shisheng He

Shanghai Tenth People's Hospital

Minimally invasive lumbar fusion technology is welcomed by doctors and patients because of its small amount of trauma and rapid recovery. At present, the clinical application of endoscopic lumbar interbody fusion technology can be divided into uniportal and unichannel coaxial endoscopy, unilateral bichannel endoscopy and MED assisted lumbar interbody fusion.

Innovatively, V-shape Bichannel Endoscopy system, a new type of spinal endoscopy, enables uniportal bichannel spinal endoscopy assisted lumbar interbody fusion with one incision. With two channels, the VBE system enables surgeons to complete surgical procedures through the working channel under monitoring through the endoscopy channel.

In this part, we will introduce the VBE system and show its application in lumbar fusion under full-time and real-time monitoring.



Spinal endoscopic visualized technique for the treatment of lumbar lateral recess stenosis

En Song

the First Affiliated Hospital of Kunming Medical University

Objective

Lumbar spinal stenosis is a common lumbar vertebrae disease in the elderly population, can lead to leg pain and low back pain especially when walking. The aim of this retrospective study was to evaluate the efficacy and safety of spinal endoscopic visualized technique for the treatment of lumbar lateral recess stenosis.

Methods

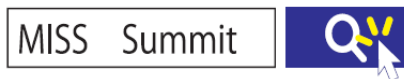August 2019 to December 2020, 29 elderly patients (18 males and 11 females) with symptomatic lateral recess stenosis were underwent spinal endoscopic visualized technique therapy. Clinical outcomes were evaluated by the visual analog scale (VAS) score of pain, Oswestry disability index (ODI) and the modified MacNab criteria before operation and at 1 month, 6 months, and 1 year after the operation. Surgical outcomes including operative time, the quantity of bleeding and complications were also investigated.

Results:

All surgical procedures were successfully performed by one experienced orthopedic surgeon with an average operation time of 45.31 ± 12.58 minutes, the quantity of bleeding was 24.72 ± 8.67 ml. Patients were followed up for a mean duration of 8.65 ± 2.22 months. There were significant differences in VAS and ODI between preoperative and postoperative score ($P < 0.01$). There was no significant difference in the visual analog scale and Oswestry Disability Index scoring between postoperative 1 months, 3 months, and final follow-up ($P > 0.05$). According to the modified MacNab criteria at the final follow-up, the excellent and good rate were obtained in 93.10%, except 2 cases without obvious improvement.

Conclusions We considered that spinal endoscopic visualized technique for the treatment of two-level lumbar lateral recess stenosis is an safe and effective treatment for patients with lumbar spinal stenosis.

Keywords: Lumbar spinal stenosis, Lateral recess stenosis, spinal endoscopic visualized technique

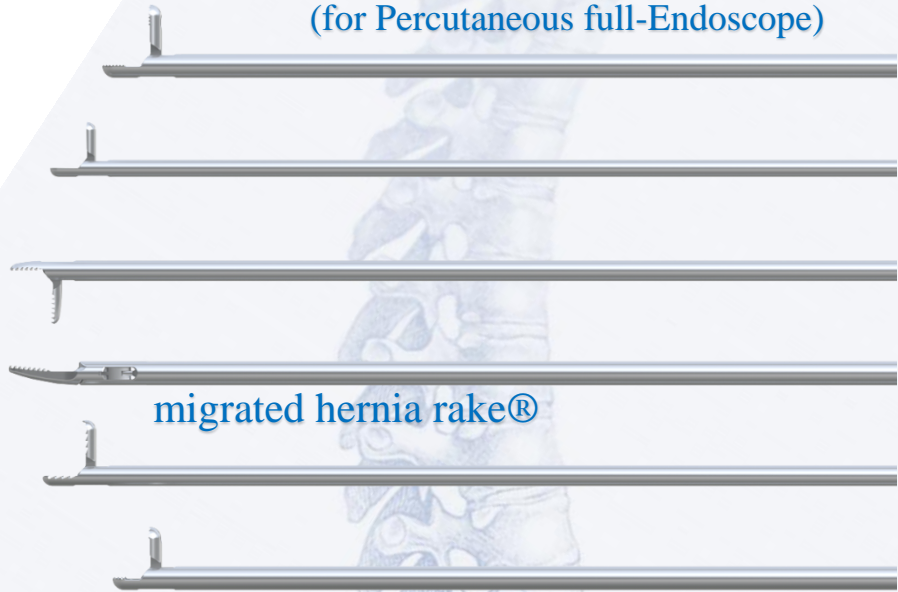
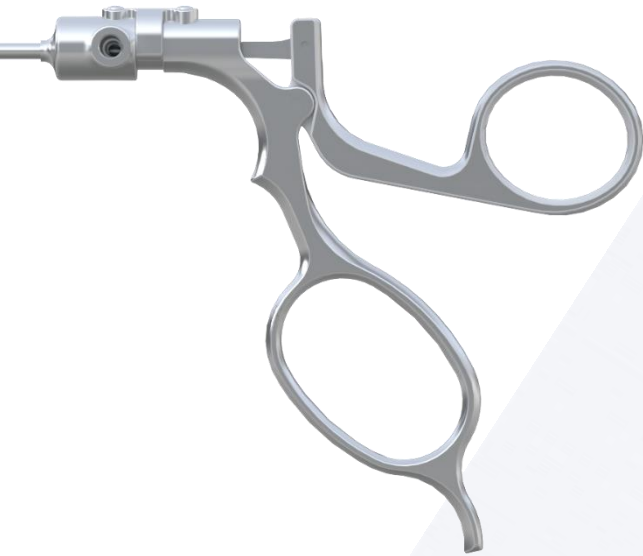

Aichi Spine Hospital

31-1 kamiike, goroumaru, Inuyama-shi, Aichi, 484-0066, Japan

ADACHI INDUSTRY


Working instruments (各種)
(for Percutaneous full-Endoscope)




migrated hernia rake®



内レトラクター®



PELIF®
(Percutaneous Lumbar
Interbody Fusion)



※画像は現物大ではありません

フェジ鉗子：製造販売届出番号：21B2X10011000001

経皮的全内視鏡内レトラクター：製造販売届出番号：21B2X10011000003

アウターシースカッター：製造販売届出番号：21B2X10011000004

レトラクトスライダー：製造販売届出番号：21B2X10011000005

トレフィンセット：製造販売届出番号：21B2X10011000006

足立工業株式会社

〒501-3263 岐阜県関市広見 113-2

TEL 0575-22-0052

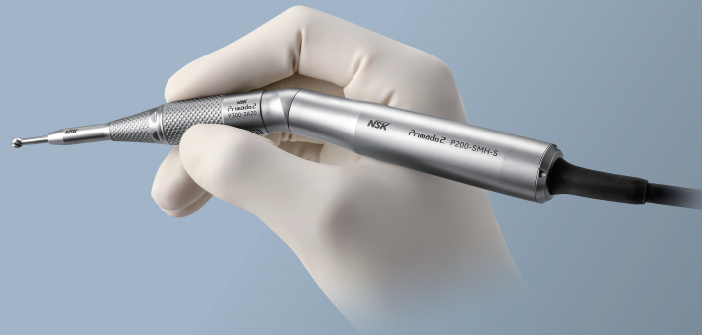<http://www.adachikk.co.jp/contents/>

プリマド2 コントロールユニット




販売名：プリマド2 認証番号：223ALBZX00026000

スリムモーターハンドピース ショート



販売名：プリマド2 認証番号：223ALBZX00026000

クワッドエッジバー



販売名：NSK 滅菌済バー・ドリル
認証番号：222ALBZX00010000

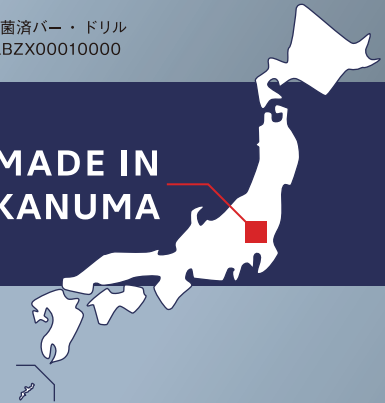NSK Create it

製造販売元



株式会社ナカニシ www.nsk-surgery.com

〒322-8666 栃木県鹿沼市下日向700 TEL: 0289(64)3380 FAX: 0289(64)3890

MADE IN
KANUMA



スタンダードアタッチメント300



販売名：スタンダードアタッチメント300 届出番号：09B2X00016000152

スリムアタッチメント300

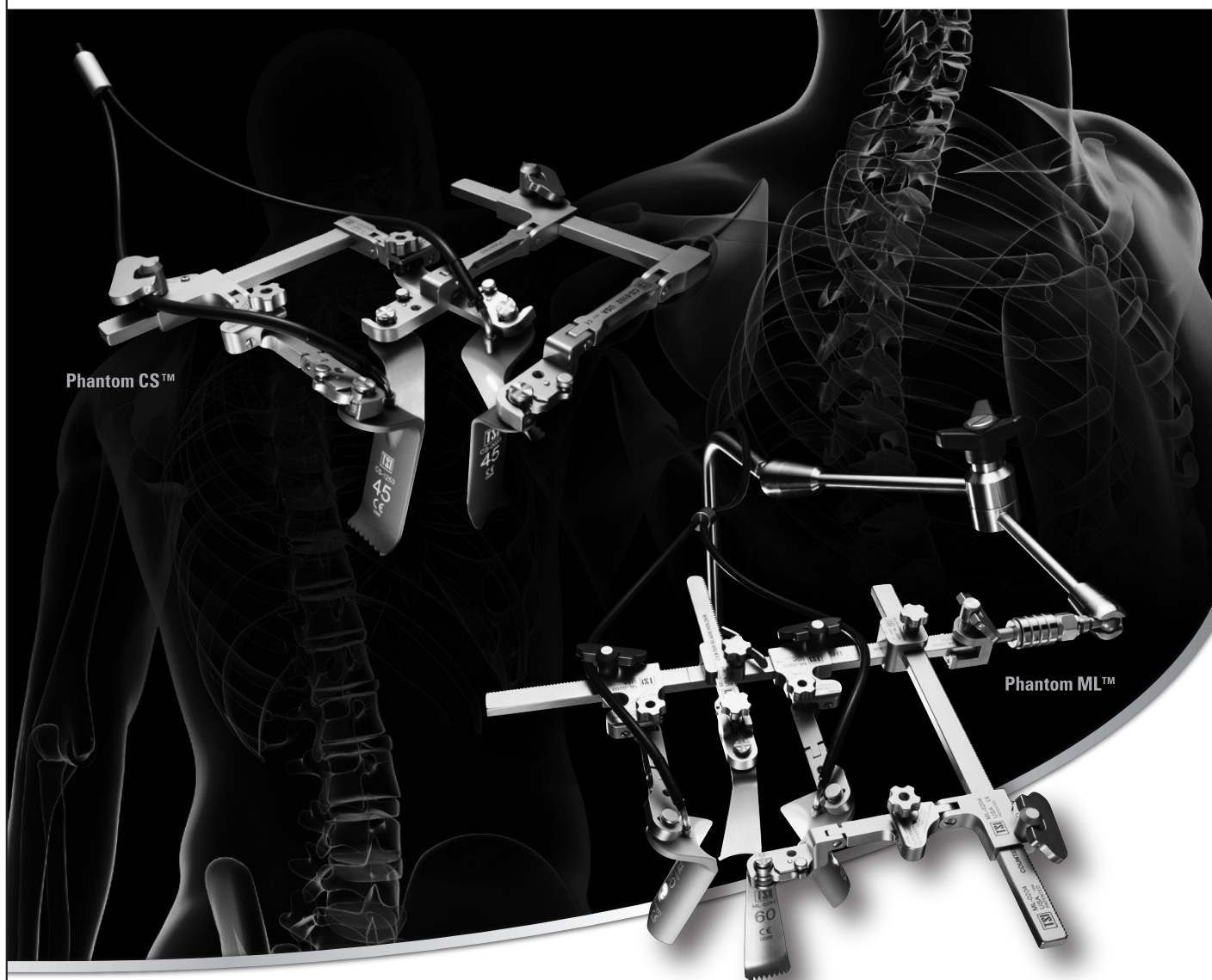

販売名：スリムアタッチメント300 届出番号：09B2X00016000151

全ての術野を明るく照らす。

TEIJIN

Human Chemistry, Human Solutions



- 頸椎から腰椎まで、MISからOPEN surgeryまで対応のトータルシステム
- 自然な色の見え方と長寿命を両立するLED光源装置
- リユースタイプのライト用ケーブル

Phantom CSTM/MLTM

Retractor System

 帝人ナカシマメディカル株式会社

〒709-0625 岡山市東区上道北方688-1
TEL. 086-279-6278 FAX. 086-279-9510

販売名: Phantomレトラクターシステム
医療機器製造販売届出番号: 33B1X100011E0012

外国製造業者
テダン サージカル イノベーションズ社 (アメリカ合衆国)

エレクトロニクスで病魔に挑戦

 NIHON KOHDEN

より美しく、しなやかに


eXcellent and eXpandable. Neuropack X1 Top of Tops.

ハイエンドスタンダード Neuropack X1

筋電図・誘発電位検査装置

MEB-2300シリーズ ニューロパック X1

6/12ch. EMG/EP Measuring System

- 新提案、6チャンネル/
12チャンネルのラインアップ
- アーチファクトの少ない美しい波形を測定。
新開発のアクティブ電極ケーブル
- 操作しやすい、
小さなソマトコントローラ 
- モンタージュ方式の18bit高性能入力箱

販売名: 筋電図・誘発電位検査装置 MEB-2300シリーズ ニューロパック X1

医療機器認証番号 | 221ADBZX00003000

62A-0548



<製造販売>

日本光電 東京都新宿区西落合1-31-4
〒161-8560 ☎03(5996)8000

*カタログをご希望の方は当社までご請求ください。

<http://www.nihonkohden.co.jp/>



KONICA MINOLTA

Giving Shape to Ideas



高解像 高感度 高画質

AeroDR *fine*

誰も見たことのない“AeroDR”の新境地

高解像 100 μ m

高DQE 56%*¹

高い把持性

MIL規格*²

耐荷重 400kg*³

防水性能 IPX6*⁴

AeroDR fineは、「デジタルラジオグラフィ SKR 3000」(製造販売認証番号:228ABBZX00115000)の呼称です。*1:1mR,1cycle/mm *2:Method 516.7 Procedure IV Transit Drop: 48インチ(122cm)の高さから、合板の上に6平面、12稜線、8頂点、計26か所を各1回落下。*3:パネルに負荷されても画像及びパネルに影響しない耐荷重(有効画像領域全面)。測定方法は当社基準による。本製品の耐荷重性能は、無破損・無故障を保証するものではありません。*4:本製品の防水性能は、完全防水、無破損、無故障を保証するものではありません。

製造販売元:コニカミノルタ株式会社 販売元:コニカミノルタジャパン株式会社 105-0023 東京都港区芝浦1-1-1 TEL(03)6324-1080(代) <http://www.konicaminolta.jp/healthcare>



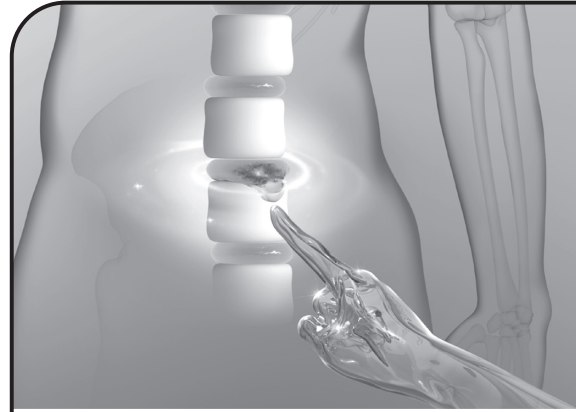
関節機能改善剤

〔処方箋医薬品〕 注意—医師等の処方箋により使用すること

日本薬局方 精製ヒアルロン酸ナトリウム注射液

アルツ®ディスポ®関節注25mg

〔製造販売元〕 生化学工業株式会社
東京都千代田区丸の内一丁目6-1



腰椎椎間板ヘルニア治療剤

〔処方箋医薬品〕 注意—医師等の処方箋により使用すること

ヘルニコア®

椎間板注用1.25単位

注射用コンドリアーゼ

〔製造販売元〕 生化学工業株式会社
東京都千代田区丸の内一丁目6-1



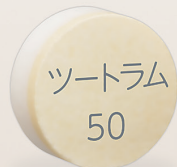科研製薬株式会社

●各製品の効能・効果、用法・用量、禁忌を含む使用上の注意等については添付文書をご参照ください。 ●各製品共、薬価基準収載

発売元〔文献請求先及び問い合わせ先〕
科研製薬株式会社 医薬品情報サービス室
〒113-8650 東京都文京区本駒込2丁目28-8

(2020年12月作成) 2AH02CK

新発売



持続性鎮痛剤

1日2回投与型トラマドール塩酸塩徐放錠

薬価基準収載

持続性鎮痛剤

劇

ツートラム[®]錠

50mg

100mg

150mg

劇薬 処方箋医薬品 注意-医師等の処方箋により使用すること

遮放部 (着色) →

徐放部 (白色) →



効能又は効果、用法及び用量、禁忌を含む使用上の注意等については、添付文書をご参照下さい。

製造販売元

日本臓器製薬

〒541-0046 大阪市中央区平野町4丁目2番3号
資料請求先：学術部

くすりの相談窓口 ☎0120・630・093
土・日・祝日を除く 9:00～17:00

2020年12月作成

株式会社ツムラの医療関係者向けサイト

TSUMURA MEDICAL SITE

<https://medical.tsumura.co.jp>

漢方情報を
ネットから!



セミナーや講演会、
動画コンテンツなど
さまざまな漢方情報が
ご覧いただけます。

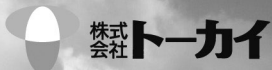

ご登録は
こちらから

<https://medical.tsumura.co.jp/reg>

Web講演会の参加申し込みや視聴予約、
オンデマンド動画のご視聴には会員登録が必要です。
医療関係者の皆様のご登録をお願いします。





手術用リネンリユースシステム

NEXSURG.[®]

ネクサージ

環境保全、医療廃棄物の削減、コストダウンを可能にする
医療現場の新時代リユースシステム



株式会社トーカイ 病院関連事業本部所在地

本部

〒500-8828 岐阜県岐阜市若宮町9丁目16番地
TEL.058-212-3766 FAX.058-266-5652

関西メンテナンス工場

〒613-0852 京都府八幡市八幡樋ノ口15番8
TEL.075-757-8050 FAX.075-757-8048

名古屋支店

〒462-0011 愛知県名古屋市北区五反田町78番地
TEL.052-902-5211 FAX.052-902-5249

株式会社トーカイ(四国)

〒761-8555 香川県高松市鶴市町205番地3
TEL.087-881-8001 FAX.087-882-0442

横浜支店

〒226-0012 神奈川県横浜市緑区上山2丁目25番25号
TEL.045-933-2241 FAX.045-933-2979

松本支店

〒399-0001 長野県松本市宮田18番23号
TEL.0263-28-1561 FAX.0263-28-1569

松阪営業所

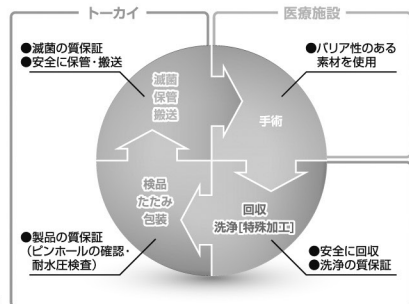
〒515-0045 三重県松阪市駅部田町203番地
TEL.0598-26-9171 FAX.0598-22-3025

中国支店

〒704-8161 岡山県岡山市東区九幡800番地1
TEL.086-948-4654 FAX.086-948-4633

ネクサージの運用プロセス

手術で使用したリネンを最新の専用工場にて、洗浄、検品、補修、畳み、セット組み、滅菌までを一貫して行います。



ネクサージの導入効果

効率性

- 回収から納品までの一括委託
- 在庫管理に関する手間を省力化
- 必要数の安定供給が可能

経済性

- 医療廃棄物の処理費用が不要
- トータルコスト削減
- 余剰在庫の削減

環境


- 医療廃棄物の発生を抑制
- リユースによる資源の有効活用
- CO2削減による環境負荷軽減

安全性

- 高いリニア性、低リントと耐久性を実現
- 徹底した検品品質管理システム
- 滅菌保証


営業エリアマップ

○…営業エリア ●…生産拠点 ○…営業拠点



しあわせをかたちにする
人と技術の会社です。

確かな知識と技術
温かいハートで
求められる製品をお届けしています。



補装具のオーダーメイドを承ります (社)日本義肢協会登録・中部107号

株式会社 **松本義肢製作所**

本 社：〒485-8555 愛知県小牧市大字林 210 番地の 3
tel. (0568) 47-1701 fax (0568) 47-1702
営業時間 午前8時30分～午後5時 休業日：日・祝日

介護用品・自助具・リハビリ用品専門店

♡ **ハートフル/ショップ/エイト**®
「もっと!」こころづかいハートウェアのお店



〒461-0013 愛知県名古屋市東区飯田町 51 番地
tel. (052) 939-3577 fax (052) 939-3578
営業時間 午前10時～午後7時 休業日：日・祝日

名古屋 営業所・ハートフルショップエイト・睡眠姿勢く～すか
静岡 営業所・靴工房
長野 営業所

tel. (052) 939-3577
tel. (054) 288-1115
tel. (0263) 48-2061



設備管理、警備、清掃、工事、オフィス商品販売まで
トータルに病院・介護施設の運営をサポート



星光ビル管理株式会社

東海営業第二部

名古屋市中村区那古野1-38-1
TEL: 052-583-0951

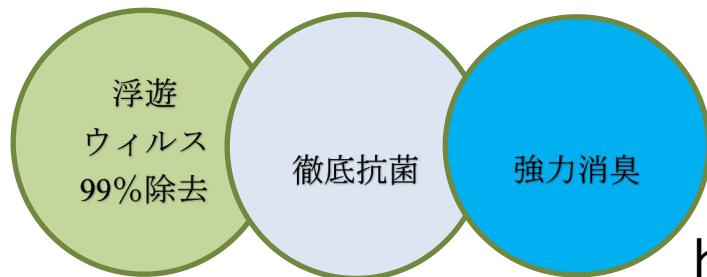
本社

大阪府中央区伏見町4丁目4-1
TEL: 06-6201-0021 (代表)

除菌濃度切替付（通常モード+無人モード）40畳まで対応

オゾンで気軽に空間を除菌・消臭・清潔な空間を作ります

Fresh Pro



[http://baba@babakikai.jp](mailto:baba@babakikai.jp)

株式会社馬場器械店 TEL.052-901-1567

希望小売価格: ¥120,000(税別)→80,000(税込)

今ならA3ポスター付、待合に如何ですか